

ROLE OF MOSS MIAMI PEDICLE SCREW SYSTEM IN UNSTABLE SPINAL INJURIES

Dr Muhammad Asad Qureshi *, Dr Ahmed Bilal Khalique **

ABSTRACT

Objective: To find out the role of instrumentation with MOSS Miami (by DePuy, Johnson and Johnson) implants to treat patients with unstable thoraco-lumbar spinal fractures and dislocations in terms of stability achieved and improvement in neurological status.

Design: Quasi-experimental study.

Place and Duration of Study: This study was conducted in orthopaedic department of Combined Military Hospital Rawalpindi from Oct 2001 to Oct 2004.

Patients and Methods: 80 patients with unstable spinal injuries were operated during above time period. 48 patients underwent posterior transpedicular MOSS Miami instrumentation of thoraco-lumbar spine. Instability was defined according to White and Panjabi's criteria. Neurological deficit was defined according to American Spinal Injuries Association (ASIA) Impairment Scale (AIS). Those with complete injury were placed in group I (29 cases) and rest were assigned group II (19 cases). All cases were treated by open reduction and short segment internal fixation using MOSS Miami pedicle screw system. Patients were followed up 2 weeks, 6 weeks, 3 months, 6 months and yearly after operation. Patients were observed for correction of deformity, spinal fusion, improvement in neurological status, loss of reduction over time, back pain and rehabilitation. All data was put in a dedicated MS Access Data Base and analysed using SPSS.

Results: It was observed that those with complete neurological deficit only 5 cases improved out of 29 cases and the mean AIS improvement was 0.39 /case. Out of those with partial neurological deficit, all cases showed improvement. There was no deterioration in neurological status. Mean AIS improvement was 1.4 /case. Solid spinal union was observed in 45 cases out of 48 cases at the end of 3 months. 03 cases had implant related complications. The vertebral deformity was completely restored in 32 cases and incompletely in 16 cases. Loss of reduction was 2.5° on average.

Conclusion: MOSS Miami pedicle screw system is safe and effective for posterior short segment fixation of unstable thoraco-lumbar fractures.

KEYWORDS: Spinal injuries. Thoracolumbar fractures. Spinal instability. Transpedicular instrumentation. MOSS Miami.

* Consultant Orthopaedic Spinal Surgeon

** Resident Orthopaedic Surgeon

Orthopaedic department, Combined Military Hospital, Rawalpindi

For correspondence:

Dr Muhammad Asad Qureshi, Consultant Orthopaedic Spinal Surgeon, Orthopaedic department, CMH Rawalpindi.

Tel: 051 56130040, 051 5565594, 0300 9563865

Email: asad.qureshi@yahoo.com , drdoormouse@yahoo.com

INTRODUCTION

The treatment of unstable fractures and fracture dislocations of the thoracic and lumbar spine has long been controversial. In the past non opera-

tive treatment was emphasized.¹ In the recent times the balance has shifted more towards open reduction and internal fixation especially for those with neurological deficits,² which was revolutionised due to the invention of rigid implants and improved fixation techniques.³

Segmental instrumentation systems have replaced non-segmental systems in all areas of spine surgery.⁴ Construct patterns for fracture stabilization have been adapted from deformity experience and from biomechanical studies using segmental systems.⁵ Few studies have been completed to validate the use of these implants in trauma or to assess their relative strengths and weaknesses.¹

The implants can be placed anteriorly using anterior fixing devices or posteriorly or both anterior and posterior instrumentation. Though with the advent of newer more rigid systems either anterior or posterior instrumentation is considered sufficient.^{6,7}

In patients with unstable fractures and neurological deficit early surgery is advocated.^{8,9} Decompression can be accomplished in a number of ways. Anterior approach and postero-lateral approach, a combination of both approaches can also be used if needed.¹⁰ Quite effective decompression is also possible using ligamentotaxis.¹¹

The short segment fixation for burst fractures and fracture dislocation had been fraught with a high incidence of hardware failure,¹² but good results have been obtained with use of pedicle screws and rods.¹³ MOSS Miami (By DePuy Johnson and Johnson) is a pedicle screw and multi type hook system which is very versatile and can be used to fix most of the thoraco-lumbar spinal diseases¹⁴ and has shown promising results.¹⁵

PATIENTS AND METHODS

A quasi-experimental study was carried out on patients presenting with unstable fractures and dislocations of the thoracic and lumbar spine from Oct 2001 to Oct 2004 in the department of orthopaedic and spinal surgery, Combined Military Hospital

(CMH), Rawalpindi.

CMH Rawalpindi is a tertiary care hospital and receives patients of thoraco-lumbar trauma from all the formations of Army from all over Pakistan. In addition, families and civilians avail the treatment facilities present as well. The study was approved by the local ethical committee and written and informed consent was taken from all the patients.

INCLUSION CRITERIA

1. Having Thoracic and Lumbar spine fracture of burst or fracture dislocation types (according to Denis' classification) (Table1).
2. No previous spinal surgery.
3. No history of pathological fracture or hereditary bone disease.
4. No congenital spinal abnormality/defor mity.
5. Patients must have reached the complete vertebral column maturity.
6. The vertebrae fractured must be continuous and there should be no jump fractures.
7. The total number of vertebrae fractured should not be more than 3.
8. The fracture must be of a closed variety.

Table 1: Dennis's Classification of Major Thoraco-lumbar Injuries based on three column concept.

Type of Fracture	Description	Columns involved
Denis A	Wedge compression fracture	Anterior column injury
Denis B	Burst fracture	Anterior and middle column injury
Denis C	Flexion distraction injury (Chance fracture)	Posterior and middle column injury
Denis D	Fracture dislocation	All three columns involved

All the cases were diagnosed on the basis of history, clinical examination and imaging studies. The neurological deficit was carefully noted, both the level and degree of impairment according to ASIA scale (Table: 2). The functions of bladder and bowel

were also recorded. The findings were confirmed using X-rays. Either CT Scan or MRI was done in all cases.

Table 2: ASIA (American Spinal Injuries Association) Impairment Scale (AIS)

AIS – A	Complete motor and sensory loss
AIS – B	Only sensations are present but no motor power (grade 0/5)
AIS – C	Motor power grades 1-3/5
AIS – D	Motor power grade 4/5
AIS – E	Full neurological recovery

The patients were all operated by the same consultant using posterior approach plus MOSS Miami pedicle instrumentation. (Figure 1)

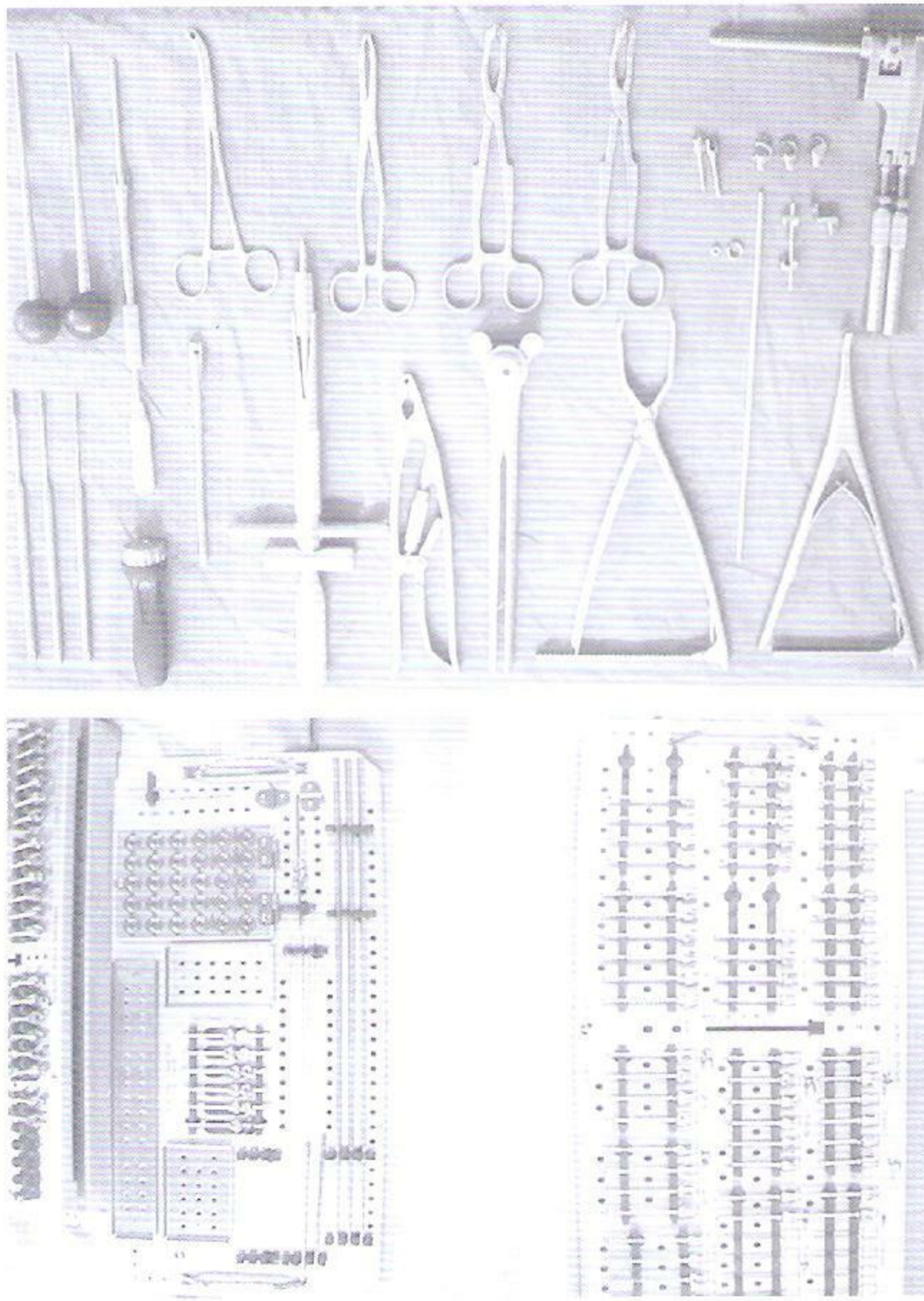


Figure 1: MOSS Miami, (by DePuy, Johnson and Johnson) product range.

SURGERY FOR BURST FRACTURE WITH INTACT POSTERIOR LONGITUDINAL LIGAMENT

Those with burst fracture were treated on the following lines:-

1. Trans-pedicle screws placement and rods attached.
2. Distraction – ligamentotaxis applied.
3. Trans pedicular reduction of fracture (if not achieved already by ligamentotaxis).
4. Trans-pedicular bone grafting.
5. Postero-lateral bone grafting.

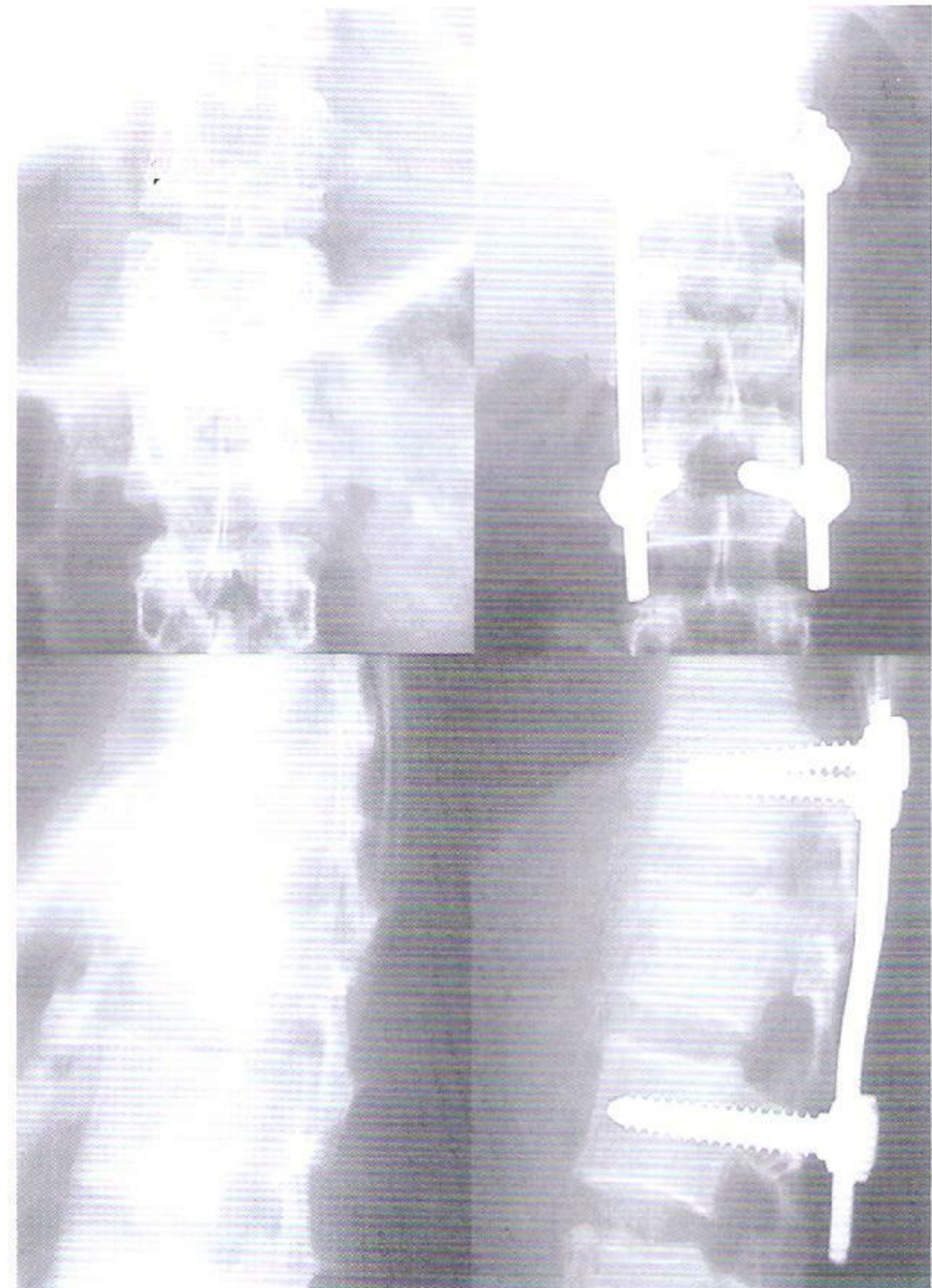


Figure 2: Pre-op and post op X-rays of patient with burst fracture reduced and then fixed with MOSS Miami implant using posterior approach.

SURGERY FOR FRACTURE DISLOCATION AND THOSE WITH TORN POSTERIOR LONGITUDINAL LIGAMENT

1. Trans pedicular screw placement.
2. Reduction of deformity by manipulation.
3. Cord decompression by postero-lateral approach or laminectomy if not already decompressed by manipulation.
4. Application of rods.
5. Postero-lateral grafting.
6. Application of transverse connectors for rotational stability.

In all cases the screws were applied under radiographic guidance. The metal work was extended to one vertebra above and one below the fracture site. AO funnel was used for transpedicular grafting.

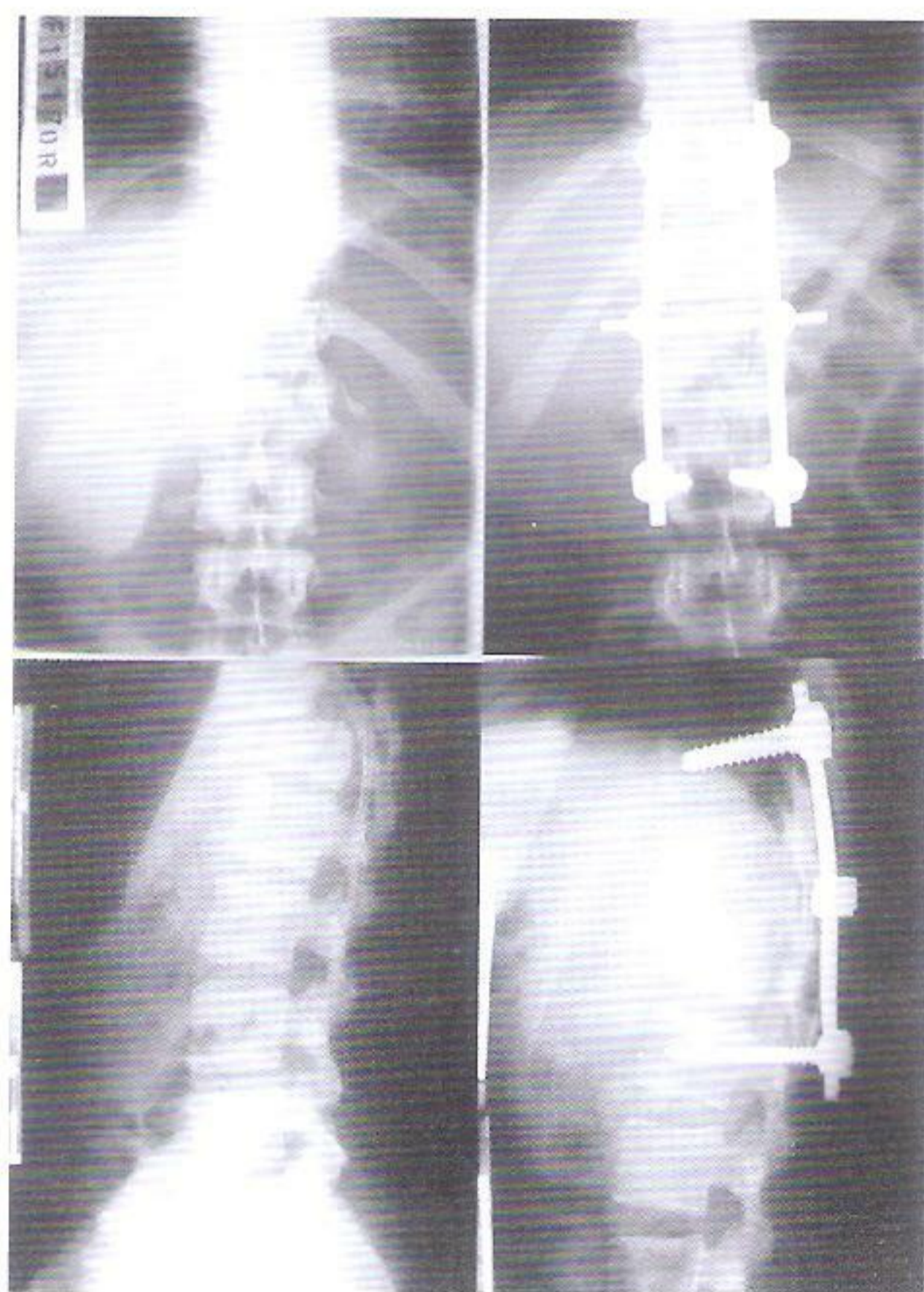


Figure 3: Pre-op and post op X rays of patient with fracture dislocation reduced and then fixed with MOSS Miami implant using posterior approach

The cases were mobilized out of bed as soon as possible usually within 5 days of surgery and all of them were seen by a Rehabilitation Medicine fellow

and regular physiotherapy sessions were started as soon as the patient was pain free.

The patients were followed up 2 weeks, 6 weeks, 3 months, 6 months and yearly after operation on regular basis, documenting correction of deformity, spinal fusion, improvement in neurological status (according to ASIA impairment scale), loss of reduction over time, back pain and rehabilitation. The bone union was determined using X-rays on every OPD visit. The patient's records were kept in a dedicated computer with a purpose built database using Microsoft Access®.

The patients were divided into two groups depending upon the deficit; those with complete neurological deficit and those with incomplete injuries to the cord. The data was characterised in age, gender, level of injury, diagnosis of fracture type, degree of deformity, neurological deficit on presentation and change on every OPD visit, the number of grades improved from day of presentation and at the end of follow up period, the level of rehabilitation and presence of pain, any complication (implant failure, pseudarthrosis etc). The descriptive statistics were applied.

RESULTS

48 cases were selected which met the above mentioned criteria, the main reason for not meeting the criteria was multiple fractures of spine and penetrating injuries. They were observed over from a period of 6 months to 2½ years, the average follow up period was 18 months. There were 46 males (95.83%) and 2 females (4.16%). A male to female ratio 23:1 was recorded. The age ranged from 18 years to 60 years. Majority of these cases were from 25 to 35 years of age (43.66%).

Out of 48 cases 26 cases involved thoracic spine and 22 involved lumbar spine (individual number of fractures encountered at each level is given in Figure 4. We grouped our patients into two groups, group I comprised of those patients with complete neurological deficit and group II comprised of those with incomplete injuries to the spinal cord. Among the

types of fractures encountered burst fractures were the most common 25 cases (52.08%) and the fracture dislocations were 23 cases (47.91%).

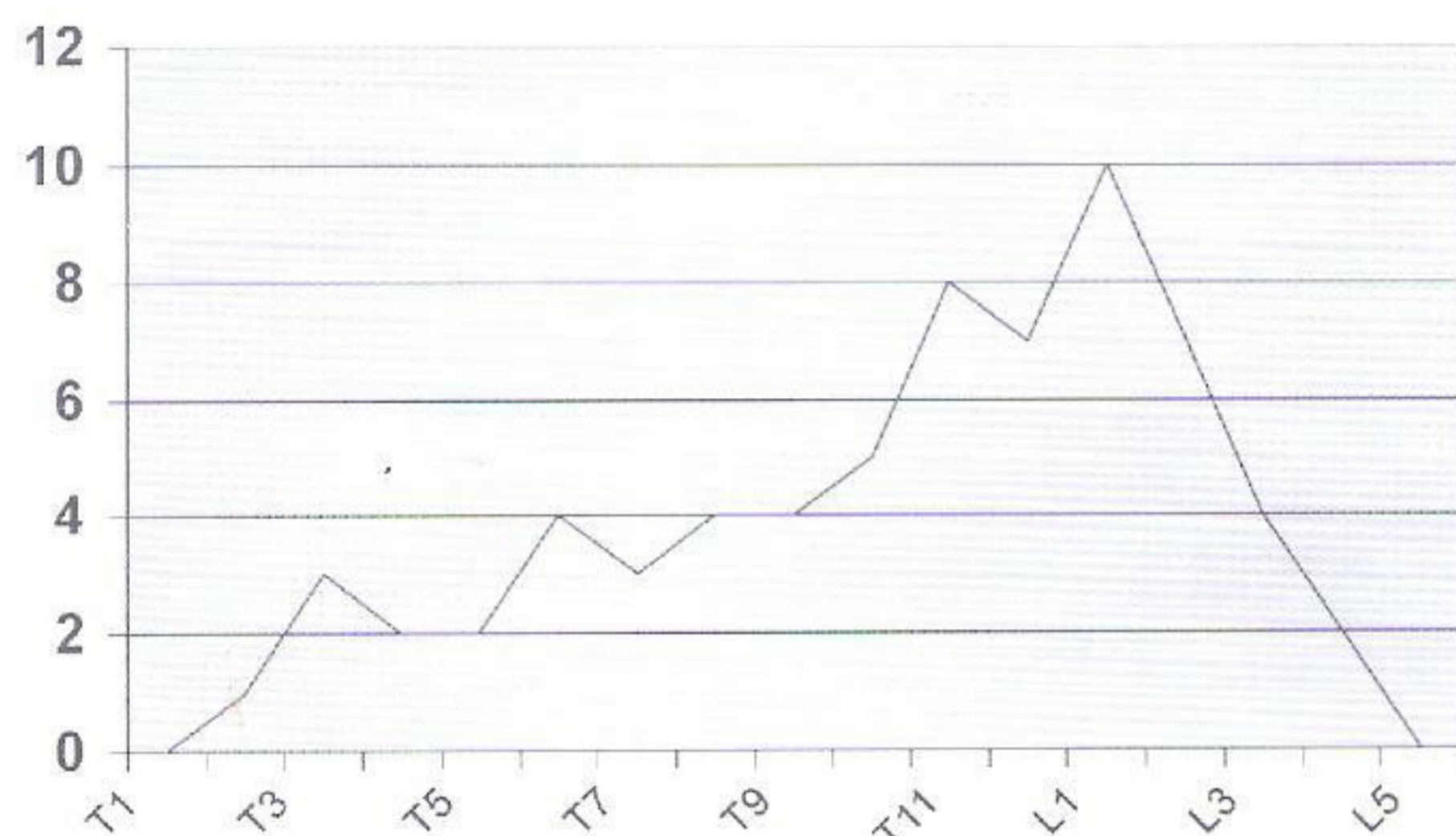


Figure 4: Frequency of fractures encountered at each vertebral level.

In group I there were 29 cases (AIS A) which included 5 cases (17.24%) involving lumbar spine and 24 cases (82.75%) involving thoracic spine. 24 cases (82.75%) failed to show any improvement. One case showed complete recovery of spinal cord functions (AIS E), three cases were in AIS C at the end of follow up period and one case improved till AIS B. Overall in this group, recovery was recorded in 05 cases (17.24 %). The average improvement in this group was 0.3925 grade/case.

In group II we included cases with AIS impairment B, C, D and E. The total number of cases in this group was 19. This group included 16 cases involving lumbar vertebrae and 3 cases involving thoracic vertebrae. The number of cases with AIS B was 3, AIS C was 8, AIS D was 5 and AIS E was 3. These were observed upto a period of 02 years. None of the cases showed deterioration in cord functions after surgery and recovery was seen in all cases (Table 3) below.

Table 3 : Showing individual improvement or deterioration in group II patients with incomplete neurological deficit. (n = 19)

AIS B cases		
Total no of cases	3	
Number showing 1 grade improvement (AIS C)	1	33.33%
Number showing 2 grade improvement (AIS D)	2	66.66%
AIS C cases		
Total no of cases	8	
Number showing 1 grade improvement (AIS D)	3	37.5%
Number showing 2 grade improvement (AIS E)	5	62.5%
AIS D cases		
Total no of cases	5	
Number showing 1 grade improvement (AIS E)	5	100.00%
AIS E cases		
Total no of cases	3	
Number of cases with same neurological status	3	100%

Important to note is that if only patients with incomplete cord injuries are included i.e. those in Grade B, C and D, their total number is 16. A complete neurological recovery was seen in 10 cases (62.5%) whereas neurological recovery was documented in all the cases.

Overall it was observed that in 3 cases (6.25% of the total) the spine failed to unite and there was pseudoarthrosis. Implant related complications were seen in these 3 cases (6.25%), in all cases it was breakage of screws. In one of the cases the spine united afterwards. The infection was not seen in any case. The average improvement seen was 0.7083 grade/case.

The angle of the kyphosis of vertebral body was on average 21.8 degrees preoperatively. The vertebral body was completely restored in 32 (66.66%) cases and incompletely in 16 cases (up to 5 degrees angle of residual deformity). The correction of kyphosis was achieved on average 20.5 degrees and on follow up the loss of correction was observed to be 2.5 degrees on average.

DISCUSSION

The treatment of thoracolumbar fracture in-

volves many factors which are involved in the final outcome of the disability.

The fracture reduction can be achieved in a number of ways as already described above. We used ligamentotaxis and manipulation in our study. The mechanical force is applied by forced distraction of the vertebrae involved. The ligamentotaxis is quite effective in thoracic and upper lumbar vertebrae, but not for lower lumbar vertebrae (L4-L5)¹⁰. Further the natural remodelling of spine decreases the canal stenosis.¹

While using the posterior approach there are certain limitations to it. In case of posterior instrumentation with pedicle screw systems including MOSS Miami (by DePuy, Johnson and Johnson) two sets of screws are to be applied, thereby making it essential for its application, the intactness of elements on both the sides.⁵ While placing screws it is helpful to insert them under radiographic guidance there by limiting complications related to transpedicular screw placement¹⁹ which commonly include; pedicle fractures, dural tear, nerve root injuries, vascular injuries^{15,2} and long term complications such as failed reductions and fusion.^{3,4} In our study, to limit the incidence of complications we used radiographic guidance and none of the above mentioned complications¹⁵ developed in our patient.

The fixating elements provide rigid fixation during the healing phase. It has been documented that pedicle screws are far better an implant as compared to the hooks especially in the axial rotation⁵. Further advantage offered by MOSS Miami instrumentation is by providing the dual attachment of every screw to the rod.¹⁸

The profile of instrumentation is helpful in determining the aesthetics of the spine after recovery. The AO fixator interneer and other similar instrumentations have a much higher profile hence the instrumentation is felt subcutaneously in thin patients. MOSS Miami instrumentation offers a much lower profile which is not palpable¹⁸ and there is an added advantage in providing tension free closure of the skin.

Short segment fixation is fraught with complications and with the posterior instrumentation in cases done earlier with other screw, especially work by Kramer and colleagues,¹⁵ showed to have unacceptable rate of hardware failure but there was no loss of cord function in terms of Frankel grade. The main problems observed were breakage of screws, loss on angle of correction and post reduction kyphosis. Our study and those carried out with newer pedicle screw systems, have demonstrated an acceptable rate of hardware failure.⁶ It was evident in our study that hardware failure occurred only in those cases where there was a lack of union and the implant continued to bear the stress. The advantage in short segment fixation in longer run is the maximum preservation of spinal mobility.⁷

Liu CL, Wang S et al⁸ observed while using AO fixateur interneer that 7 cases out of 42 developed implant related complications, which included 4 screw breakages, 1 screw pullout and 2 patients developed other implant related complications. Comparing it with our experience with MOSS Miami only 3 cases out of 48 developed implant related complications.

The correction achieved with AO fixateur interneer was 14.2 degrees and the rate of loss of correction was 3.3 degrees on average over the period of follow up.²⁷ However, in our study with MOSS Miami we observed correction to be 20.5 degrees and the rate of loss of reduction to be 2.5 degrees.

When comparing the neurological outcome in both the groups in our study it is helpful to consider them separately. In those with complete cord injury there is no documented recovery post surgery as reported by Razak M, Mahmud M et al;⁹ also demonstrated by Spakes GS, Papagelopoulos PJ, Papadakis SA et al,⁹⁻¹⁰ but we observed a slight neurological recovery in 5 out of 29 cases. In the rest (24 cases) no significant improvement in neurological function was observed. Possibly we had a sample of much younger population to attend or there might be incomplete injuries to begin with. However, those with incomplete injuries have a much better chance of

resolution of their neurological deficits, a much better chance of recovery and we observed a much similar pattern of recovery as was observed by Calista F, Gualtieri I et al.¹²

CONCLUSION

It can be concluded that neurological recovery is unchanged with the use of MOSS Miami (by DePuy, Johnson and Johnson). In the treatment of burst fractures and fracture dislocations in the thoracic and lumbar region with short segment fixation, we observed it to be safe and effective and with an acceptable rate of complications. However, it remains to be seen, what is the overall advantage of MOSS Miami instrumentation, over other pedicle screw spine stabilizing systems. Its lower profile is advantageous in rendering the implant impalpable and helping easy closure of skin.

REFERENCES:

- 1 Tator CH, Duncan EG, Edmonds VE, Lapczak LI, Andrews DF. Comparison of surgical and conservative management in 208 patients with acute spinal cord injury. *Can J Neurol Sci.* 1987 Feb;14(1):60-9.
- 2 An HS, Simpson JM, Ebraheim NA, Jackson WT, Moore J, O'Malley NP. Low lumbar burst fractures: comparison between conservative and surgical treatments. *Orthopedics.* 1992 Mar;15(3):367-73.
- 3 Campbell's Operative Orthopaedics [Book on CD-ROM]. Marvin RL. Fractures, Dislocations and Fracture-Dislocation of Spine. In: S.Terry Canle, editor. *Campbell's Operative Orthopaedics.* 9th edition. USA: Mosby inc; 1999.
- 4 McLain RF, Burkus JK, Benson DR. Segmental instrumentation for thoracic and thoracolumbar fractures: prospective analysis of construct survival and five-year follow-up. *Spine J.* 2001 Sep-Oct;1(5):310-23.
- 5 Eichholz KM, Hitchon PW, From A, Rubenbauer P, Nakamura S, Lim TH, Torner J. Biomechanical testing of anterior and posterior thoracolumbar instrumentation in the cadaveric spine. Invited submission from the Joint Section Meeting on Disorders of the Spine and Peripheral Nerves, March 2004. *J Neurosurg Spine.* 2004 Jul;1(1):116-21.
- 6 Danisa OA, Shaffrey CI, Jane JA, Whitehill R, Wang GJ, Szabo TA, Hansen CA, Shaffrey ME, Chan DP. Surgical approaches for the correction of unstable thoracolumbar burst fractures: a retrospective analysis of treatment outcomes. *J Neurosurg.* 1995 Dec;83(6):977-83.
- 7 Been HD, Bouma GJ. Comparison of two types of surgery for thoraco-lumbar burst fractures: combined anterior and posterior stabilisation vs. posterior instrumentation only. *Acta Neurochir (Wien).* 1999;141(4):349-57.
- 8 Chipman JG, Deuser WE, Beilman GJ. Early surgery for thoracolumbar spine injuries decreases complications. *J Trauma.* 2004 Jan;56(1):52-7.
- 9 Schlegel J, Bayley J, Yuan H, Fredricksen B. Timing of surgical decompression and fixation of acute spinal fractures. *J Orthop Trauma.* 1996;10(5):323-30.
- 10 Been HD, Bouma GJ. Comparison of two types of surgery for thoraco-lumbar burst fractures: combined anterior and posterior stabilisation vs. posterior instrumentation only. *Acta Neurochir (Wien).* 1999;141(4):349-57.
- 11 Kuner EH, Kuner A, Schlickewei W, Wimmer B. Significance of ligamentotaxis for internal fixator osteosynthesis in fractures of thoracic and lumbar vertebrae. *Chirurg.* 1992 Jan;63(1):50-5.
- 12 Kramer DL, Rodgers WB, Mansfield FL. Transpedicular instrumentation and short-segment fusion of thoracolumbar fractures: a prospective study using a single instrumentation system. *J Orthop Trauma.*

- 1995;9(6):499-506.
- 13 Razak M, Mahmud MM, Hyzan MY, Omar A. Short segment posterior instrumentation, reduction and fusion of unstable thoracolumbar burst fractures—a review of 26 cases. *Med J Malaysia*. 2000 Sep;55 Suppl C:9-13.
 - 14 MOSS Miami Spine System by Depuy Spine inc. in MOSS Miami™ Spine System. Updated 13/11/2004. Available from: URL: http://www.depuyacromed.com/products/deformity/moss_miami60.asp
 - 15 Lin HS, Zha ZG, Axel E. Thoracolumbar fractures treated with Moss Miami system and anterior distraction device. *Di Yi Jun Yi Da Xue Xue Bao*. 2002 Nov;22(11):1030-2.
 - 16 Ha KI, Han SH, Chung M, Yang BK, Youn GH. A clinical study of the natural remodeling of burst fractures of the lumbar spine. *Clin Orthop*. 1996 Feb(323):210-4
 - 17 Donovan DJ, Polly DW Jr, Ondra SL. The removal of a transdural pedicle screw placed for thoracolumbar spine fracture. *Spine*. 1996 Nov 1;21(21):2495-8; discussion 2499.
 - 18 Acikbas SC, Arslan FY, Tuncer MR. The effect of transpedicular screw misplacement on late spinal stability. *Acta Neurochir (Wien)*. 2003 Nov;145(11):949-54; discussion 954-5.
 - 19 Lu C, Lu GH, Ma ZM. Analysis of complication in the spinal pedicle screw internal fixation. *Hunan Yi Ke Da Xue Xue Bao*. 2000 Feb 28;25(1):51-2.
 - 20 An HS, Singh K, Vaccaro AR, Wang G, Yoshida H, Eck J, McGrady L, Lim TH. Biomechanical evaluation of contemporary posterior spinal internal fixation configurations in an unstable burst-fracture calf spine model: special references of hook configurations and pedicle screws. *Spine*. 2004 Feb 1;29(3):257-62.
 - 21 Razak M, Mahmud MM, Hyzan MY, Omar A. Short segment posterior instrumentation, reduction and fusion of unstable thoracolumbar burst fractures—a review of 26 cases. *Med J Malaysia*. 2000 Sep;55 Suppl C:9-13.
 - 22 Boucher M, Bhandari M, Kwok D. Health-related quality of life after short segment instrumentation of lumbar burst fractures. *J Spinal Disord*. 2001 Oct;14(5):417-26.
 - 23 Liu CL, Wang ST, Lin HJ, Kao HC, Yu WK, Lo WH. AO fixateur interne in treating burst fractures of the thoracolumbar spine. *Zhonghua Yi Xue Za Zhi (Taipei)*. 1999 Sep;62(9):619-25.
 - 24 Razak M, Mahmud M, Mokhtar SA, Omar A. Thoracolumbar fracture—dislocation results of surgical treatment. *Med J Malaysia*. 2000 Sep;55 Suppl C:14-7.
 - 25 Sapkas GS, Papagelopoulos PJ, Papadakis SA, Themistocleous GS, Stathakopoulos DP, Efstathiou P, Sapoutzi-Krepia D, Badekas Ach. Thoracic spinal injuries: operative treatments and neurologic outcomes. *Am J Orthop*. 2003 Feb;32(2):85-8.
 - 26 Wang MY, Hoh DJ, Leary SP, Griffith P, McComb JG. High rates of neurological improvement following severe traumatic pediatric spinal cord injury. *Spine*. 2004 Jul 1;29(13):1493-7; discussion E266.
 - 27 Calista F, Gualtieri I, Conti P, Frontali P, Bianco T, Gualtieri G. The results of the surgical treatment of 64 patients with thoracic and lumbar fracture. *Chir Organi Mov*. 2002 Apr-Jun;87(2):109-16.

