

CORRESPONDENCE

Inadvertent bronchial intubation by tracheostomy tube in advanced duchenne muscular dystrophy

Dheeraj Kapoor, MD, FCCP, FACEE, FCCS*, Shikha Sachan, MD**,
Manpreet Singh, MD, FCCP, FIMSA, FACEE, FCCS*, Jasveer Singh, MD*

**Assistant Professor, **Senior Resident
Govt. Medical College and Hospital, Chandigarh-160030, (India).*

Correspondence: Dr. Dheeraj Kapoor, 1207, Sector 32 B, Chandigarh-160030, (India);
Phone: 911724622549, 919646121549; E-mail: kapoor.dheeraj72@gmail.com, dheeraj.kapoor72@gmail.com

There are certain concerns which need special attention in advance duchenne muscular dystrophy (DMD) such as anomalous airway anatomy, choking, risk of aspiration, nocturnal hypoventilation and frequent chest infections. Tracheostomy remains a choice in these patients, particularly those with impairment of bulbar-innervated musculature.^[1] There may be a possibility of repeated endobronchial migration of tracheostomy tube (TT) due to the inherent airway abnormalities leading to airway trauma and refractory bronchospasm, which can delay the weaning process significantly.

A 19 year old boy with a diagnosis of DMD with severe thoracolumbar scoliosis (Cobb's angle of 55°) was admitted in our ICU following severe respiratory failure. During his stay in ICU, he suffered repeated episodes of refractory bronchospasm leading to significant delay in weaning process. On investigating the cause, we found endobronchial malposition of the distal end of tracheostomy tube in right principle bronchus (Figure 1). We replaced the

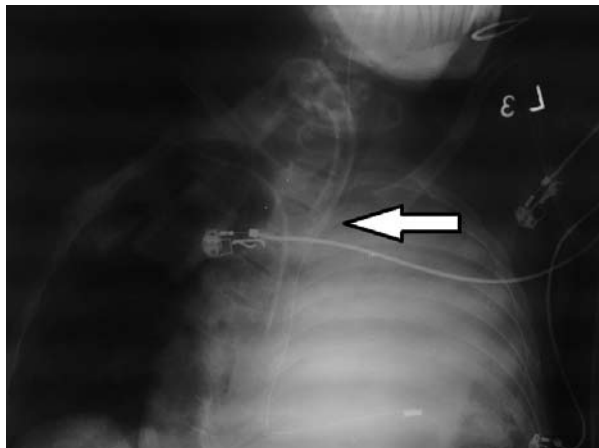


Figure 1: Arrow showing right endobronchial position of tracheostomy tube

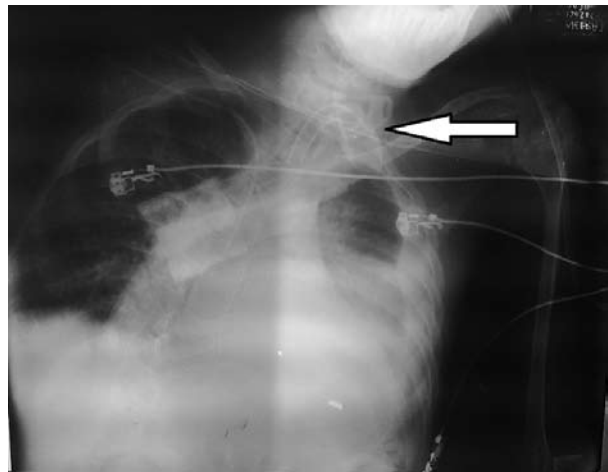


Figure 2: Arrow showing mid tracheal position of tracheostomy tube (with an adjustable fixation collar)

conventional tracheostomy tube with another tube of same size but with an adjustable fixation collar (Vygon®). The flange was adjusted with tip of tracheostomy tube (distal end) at mid trachea and confirmed on chest X-ray (Figure 2) and fiberscope. Decline in peak airway pressures were immediately observed and patient was subsequently weaned off from the ventilator successfully.

DMD patients associated with severe scoliosis are well known to have distorted airway anatomy.^[2] In literature, we could not find any data regarding the optimal choices in TT selection in patients with airway malformations. There are certain important factors such as the width, length, curvature, flexibility, and composition of the tube which need to be considered while choosing an ideal TT in these patients. Essentially, for allowing the linear trans-laryngeal flow of air, the outer diameter (OD) of a TT should not be more than the two-thirds to three-quarters of internal diameter of trachea and the distal curvature of the tube

correspondence

should be concentric and collinear with the tracheal shape. Also, the optimal length of TT should extend at least 2 cm beyond the stoma and 1-2 cm above the carina to possibly avert endobronchial migration and airway trauma.^[3] In modern clinical practice, flexible fiberscope^[4] and advance imaging such as computed tomography (CT) scan^[5] and ultrasonography (USG)^[6] is strongly suggested to fulfill the mentioned requirements by providing precise objective data for exact dimensions of TT in this subset of patients with anomalous airway. Further, we feel that a customized TT with adjustable fixation collar (Portex® Blue Line®, Bivona® Adult TTST™ Adjustable Neck Flange Hyperflex™, Vygon®) may be an optimum choice in these

patients. These silicon tubes with adjustable fixation collar may possibly avert the potential complications such as endobronchial intubation or airway trauma in presence of the anomalous airway anatomy.^[7]

Anomalous airway anatomy is one of the major concerns and can prove to be a detrimental factor during tracheostomy tube placement. Thoughtful selection of the customized tracheostomy tube clubbed with precise estimation of airway dimensions with newer imaging modalities is a crucial factor for better clinical outcome and should be enunciated by the intensivists in this subset of patients.

REFERENCES

1. Finder JD, Birnkrant D, Carl J, Farber HJ, Gozal D, Iannaccone ST et al. Respiratory care of the patient with Duchenne muscular dystrophy: ATS consensus statement. *Am J Respir Crit Care Med* 2004;170:456-65. [PubMed]
2. Kravitz RM. Airway clearance in duchenne muscle dystrophy. *Pediatrics* 2009;123:231-35. [PubMed] [Free Full Text]
3. Sherman JM, Davis S, Albamonte-Petrick S, Chatburn RL, Fitton C, Green C et al. Care of the child with a chronic tracheostomy. This official statement of the American Thoracic Society was adopted by the ATS Board of Directors, July 1999. *Am J Respir Crit Care Med* 2000;16:297-308. [PubMed] [Free Full Text]
4. Dörfel WV, Fietze I, Hentschel D, Liebetruhl J, Rückert Y, Rogalla P et al. A new bronchoscopic method to measure airway size. *Eur Respir J*. 1999;14:783-8. [PubMed] [Free Full Text]
5. Griscom NT. Computed tomographic determination of tracheal dimensions in children and adolescents. *Radiology* 1982;145:361-4. [PubMed]
6. Kristensen MS. Ultrasonography in the management of the airway. *Acta Anaesthesiol Scand*. 2011;55:1155-73. [PubMed]
7. Walts PA, Murthy SC, DeCamp MM. Techniques of surgical tracheostomy. *Clinic chest medicine* 2003;24:413-22. [PubMed]



Low minute ventilation alarm due to endotracheal tube hole

Gurpreet Kaur*, Manju Chawla**, Adarsh Chandra Swami***, Ashwini Sharma****

Clinical associate, **Senior Resident, *Add. Director & Head, ****Consultant Anaesthesia Deptt of Anaesthesia and Critical Care, Fortis Hospital, Mohali, Punjab, India.*

Correspondence: Dr. Gurpreet Kaur, Clinical Associate, Deptt of Anaesthesia and Critical Care, Fortis Hospital Mohali, Punjab-160072 (India); Cell: 9815974429; E-mail: gurbaryah@msn.com

Minute ventilation is the product of respiratory rate and tidal volume. Low values, despite adequate tidal volume and respiratory rate setting on the ventilator can be due to several causes. A rare cause can be a hole in the endotracheal tube (ETT) due to patient's biting or chewing on it. We discuss a 34 year old lady, known patient of diabetes mellitus, rheumatic heart disease with severe mitral stenosis and chronic kidney disease. She had been referred to us from a nursing home after radical nephrectomy. Patient was on full mechanical ventilatory and inotropic support on the 5th postoperative day. A continuous ventilator alarm of low minute ventilation was noticed. The tidal volume delivered by ventilator was normal but the expired tidal

volume was persistently low. Breathing circuit was checked for disconnection and integrity. ETT cuff pressure was checked and was found to be adequate (25 mmHg). She was given additional doses of the sedatives and muscle relaxants, which further decreased the minute ventilation. There was no bronchospasm on chest auscultation. We found a small rent in the ETT at the level of molar teeth caused perhaps due to intermittent biting by the patient. In the mean time, patient's SpO₂ dropped, so the hole was blocked with sterile, gloved hand and ventilation continued to attain 100% saturation. The ETT was then changed and thus ventilation normalized.

The major goal of mechanical ventilation is to maintain

adequate alveolar minute ventilation and normal levels of partial pressure of CO₂.¹ Low minute ventilation can be due to decrease in respiratory rate, tidal volume, circuit disconnection, ETT cuff leak, insufficient gas flow, increased airway resistance, inadequate ventilatory settings, incorrect alarm settings, non delivery of gas or chest wounds allowing air escape.²

Further, ETT cuff rupture can occur due to application of lubricant or local anesthetic spray, during central venous cannulation (both subclavian and internal jugular vein

cannulation), laser beam can perforate the cuff, patient can chew a hole in or completely sever a tube, tube malposition (cuff at or above the level of vocal cords) and eccentric cuff inflation can result in leakage during mechanical ventilation. In case of a leak, direct laryngoscopy should be done to check the position of cuff.³

We opine that a bite block should be used to prevent damage to all types of oral tracheal tubes in a lightly anaesthetized or conscious patients, also the circuit should be checked in entirety to when ever an alarm goes on.⁴

REFERENCES

1. Scherf R, Carr C. Understanding Ventilation Care: Part II. On Advance healthcare Network for Nurses. Feb 24,2010. [Access Online]
2. Kane Guthrie. Ventilator alarm check list from Slideshare. [Access Online]
3. Dorsch JA, Dorsch SA. Tracheal tube. In : Zinner S. Understanding Anesthesia Equipment. Fourth Edition. USA: Lippincott William & Wilkins; 1999.p. 557-671.
4. McLean R, Houston P, Carmichael F, Bernstein M. Disruption of an armoured endotracheal tube caused by biting. Can Anaesth Soc J 1985;32(3 Pt 1):313-4. [PubMed]



Inadvertent administration of intrathecal protamine during caesarian section

Nouman I. Alvi, MRCA, FCARCSI

Consultant and Faculty, Department of Anesthesiology, Aga Khan University, Karachi Pakistan ; E-mail: nouman.alvi@aku.edu

A pregnant lady was planned to undergo an elective caesarean section under spinal block. After routine monitoring a trainee resident was ready to perform the block. The consultant stood supervising the procedure. As per standard practice, the Operating Department Practitioner (ODP) read aloud the contents of ampoule as bupivacaine, the trainee resident voiced the same and gestured to read the label and proceeded to inject the solution into the subarachnoid space. The consultant moved forward to check the ampoule when he noticed that the ampoule actually read Protamine and not bupivacaine. Meanwhile the resident had injected nearly 1.5 ml of the solution. The procedure was abandoned; surgeon informed and patient was sensitively informed of the error. Patient's vital signs and cardiocography (CTG) were observed closely, first in the theatre and then in the recovery area. She was watched for any signs of dyspnea, rashes or syncope. Her vitals remained stable, no untoward signs and symptoms were noted and patient was discharged after four hours from recovery area. Patient was examined by anesthesia team in the obstetric ward after 24 hours and found to be entirely non symptomatic and without any new abnormal physical finding. Subsequently, she had another spinal performed and had a normal baby was delivered.

Protamine is a compound of basic arginine amino acids.^{1,5} This is a precursor of Nitric Oxide (NO) and leads to NO

induced direct vasodilation and suppression of sympathetic outflow.⁵ This is believed to lead to hypotension and bradycardia.⁵ It is derived from sperm of salmon fish.¹ It has high clearance rate in the blood. It is metabolized by the proteolytic enzymes in the cerebrospinal fluid (CSF).^{2,3} Protamine is conventionally used as an antagonist of heparin. It is combined with insulin as formulation of delayed release compound.⁴ It is administered very slowly because it can lead to anaphylactoid and anaphylactic reactions.¹

This incident highlighted a safety issue in our daily practice. Reading aloud the name of an injectable drug by two individuals is a standard safety practice routine but unfortunately it becomes just a ritual when "eyes do not see what the tongue is saying". A subsequent interview with both ODP and the trainee highlighted this anomaly. The consultant reflected that he should have visually confirmed the ampoule after listening, rather than hearing the statement of two colleagues. As for the trainee resident, inaction or staying silent should not be assumed as a nod of approval by the resident. In the real world, drug accidents are a real and very possible risk. Fortunately for everyone, this drug accident did not lead to an adverse event. It has helped us identify and address safety issues after root cause analysis.

REFERENCES

1. Calvey TN and Williams NE. Principles and Practice of Pharmacology for Anaesthetists, Fifth Edition ed. Singapore : Blackwell Publishing; 2008.
2. Hamada Y1, Kameyama Y, Narita H, Benson KT, Goto H. Protamine after heparin produces hypotension resulting from decreased sympathetic outflow secondary to increased nitric oxide in the central nervous system. *Anesth Analg* 2005;100(1):33-7. [PubMed]
3. Cuzner M L, Davison A N, Rudge P. Proteolytic enzyme activity of blood leukocytes and cerebrospinal fluid in multiple sclerosis. *Ann Neurol* 1978;4:337-344. [PubMed]
4. Chapman LF, Wolff HG. Studies of Proteolytic Enzymes in Cerebrospinal Fluid: Capacity of Incubated Mixtures of Cerebrospinal Fluid and Plasma Proteins to Form Vasodilator Substances That Contract the Isolated Rat Uterus. *AMA Arch Intern Med* 1959;103:86-94. [PubMed]
5. Balhorn R. The protamine family of sperm nuclear proteins. *Genome Biology* 2007;8:227. [PubMed] [Free Full Text]

★ ★ ★ ★ ★

Bupivacaine multidose vial: “For intramuscular use only”

Tanvir Samra, MBBS, MD*, Neha Sharma, MBBS**

*Assistant Professor, **IInd Year Post graduate student (MD Anaesthesia)

*Department of Anesthesiology, Lady Hardinge Medical College, New Delhi 110001 (India);

Correspondence: Dr Tanvir Samra, C-II/ 77, Moti Bagh 1, New Delhi-110021 (India);E-mail: drtanvirsamra@yahoo.co.in; Phone: 9910703609

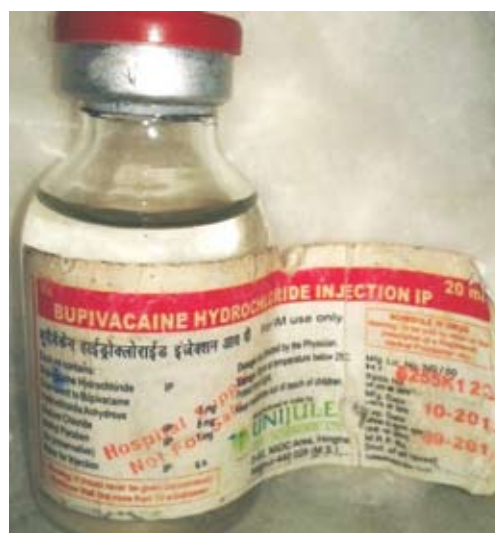Bupivacaine is the most commonly used local anesthetic for epidural and spinal anaesthesia; retrobulbar and peripheral nerve blocks and local infiltration.¹ Topical use of bupivacaine for urethral and ocular anesthesia is reported in various clinical studies.^{2,3} Intramuscular injection of 0.5% bupivacaine at cervical spinous process alleviates headache.⁴ Enhancement of hypnotic effect of propofol have been documented by prior administration of intramuscular bupivacaine.⁵

Bupivacaine is contraindicated in patients with known hypersensitivity to local anesthetic agents of the amide group or to other components of the injectable formulation and for intravenous regional anaesthesia (Bier's block). Bupivacaine hydrochloride (0.75%) is not recommended for obstetric anesthesia. Use of intra articular infusions of local anesthetics is not approved in view of post-marketing reports of chondrolysis in patients receiving such infusions.

Hypobaric multidose vials contain antiseptic preservative methylparaben which is implicated as the causative agent for allergic reactions and chronic adhesive arachnoiditis.¹ Safety of preservatives has not been established with regard to intrathecal injection also. These vials are thus used for infiltration and nerve blocks only; preservative free preparations are preferred for caudal, epidural and spinal anaesthesia.

In our public sector hospital bulk purchase of drugs and anesthetic agents is done as per need. The bupivacaine multidose vials supplied to the hospital (Figure 1) a few

months back were unique as they were labelled “For IM use only” by the manufacturer. To our knowledge there is no formulation of bupivacaine which has been marketed for intramuscular use. There was no change in the drug composition of these ‘new’ multidose vials; it contained bupivacaine (0.5%), methylparaben (1 mg/ml), sodium chloride and water. The new label on the vials was initially missed by some anesthesiologists and 25 patients had



already received either nerve block or local infiltration by the time this error was noted. These patients were followed up for a period of one month but none of them complained of any adverse effect. The manufacturer was informed of the error and the drugs were returned.

Medication error is defined as "any preventable event that may cause or lead to inappropriate medication use or patient harm while the medication is in the control of the health care professional, patient, or consumer. Error can occur at level of drug prescribing; product labelling, packaging

and nomenclature; compounding; dispensing; distribution; administration; education; monitoring; and use. The anesthesiologist must take appropriate steps to minimise the same. Any contraindication for administration of the drug to the patient also needs to be ruled out.

REFERENCES

1. Berde CB, Strichartz GR. Local Anaesthetics; In Miller RD. ed. Miller's Anaesthesia 6th ed. Philadelphia, Churchill Livingstone; 2005.:p.583-592.
2. Dawkins GP, Harrison NW, Ansell W. Urethral anaesthesia with topical bupivacaine. A role for a longer-acting agent. Br J Urol 1995 ;76:484-7. [PubMed]
3. Soliman MM, Macky TA, Samir MK. Comparative clinical trial of topical anesthetic agents in cataract surgery: lidocaine 2% gel, bupivacaine 0.5% drops, and benoxinate 0.4% drops. J Cataract Refract Surg 2004;30:1716-20. [PubMed]
4. Mellick LB, McIlrath ST, Mellick GA. Treatment of headaches in the ED with lower cervical intramuscular bupivacaine injections: a 1-year retrospective review of 417 patients. Headache 2006 ;46:1441-9. [PubMed]
5. Senturk M, Pembeci K, Menda F, Ozkan T, Gucyetmez B, Tugrul M, Camci E, Akpir K. Effects of intramuscular administration of lidocaine or bupivacaine on induction and maintenance doses of propofol evaluated by bispectral index. Br J Anaesth 2002;89:849-52. [PubMed] [Free Full Text]

★★★★★

Successful administration of spinal anesthesia using Taylor's approach for in a kyphoscoliotic patient

Tapas Kumar Singh, MD, Yogita Dwivedi, MD, Trilok Chand, MD, Chakresh Jain, MD

Department of Anesthesiology, Sarojini Naidu Medical College, Agra-282002 (India); E-mail: singh.tapas1@gmail.com

Patients with deformed spine due to scoliosis, kyphoscoliosis, or arthritis (e.g. osteoarthritis, rheumatoid arthritis, and ankylosing spondylitis), pose practical challenges to the anesthesiologist in administration of successful subarachnoid block (SAB). Rotation of spine, limited articular mobility, obliteration of the interspinal spaces, and increased difficulty in positioning the patient, all add up to complicate success by conventional midline approach. We report a case of a patient with neurofibromatosis and severe kyphoscoliosis, where midline approach for SAB was not feasible and Taylor's approach proved a useful alternative to conventional midline technique.

A 25 years old male presented for emergency above-knee amputation for crush injury after road traffic accident. History and physical examination revealed that the patient suffered from neurofibromatosis type1 (Figure 1) during childhood with appearance of multiple skin nodules and progressively developed a scoliotic spine. Bedside pulmonary function tests revealed poor respiratory reserve. Chest x-ray (PA view) revealed scoliosis with crowding of ribs (Figure 2). Rest of the investigations and hemodynamic parameters were within normal limits. Because of the emergent nature of the surgery, the patient could not be evaluated thoroughly to rule out any syndromic association and a decision to administer SAB was taken.

In the operating room, standard monitors were attached and preloading with 750 ml of Ringer lactate solution was

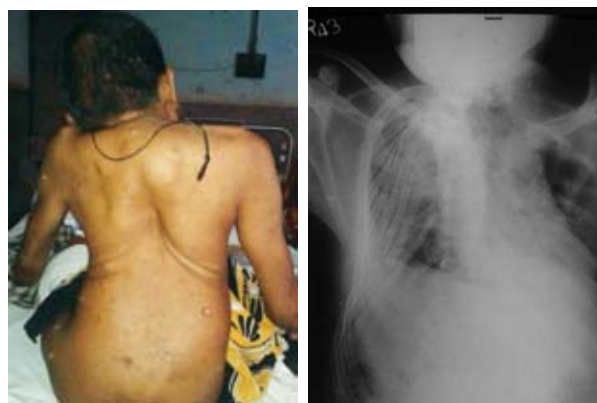

Figure 1: Back of the patient **Figure 2: Chest x-ray PA view**

done. Lumbar puncture with 27 gauge quincke needle was attempted initially by a junior resident through midline approach but the aberrant anatomy of the kyphoscoliotic spine prevented successful location of subarachnoid place. A single attempt was taken by the senior resident who was well versed with the technique and had been performing SAB using Taylor's approach regularly at L5-S1 interspace whereby the spinal needle was inserted in a cephalomedial direction through a skin wheel raised 1 cm medial and 1 cm caudal to the lowermost prominence of the posterior iliac spine. The needle was walked off the sacrum to enter the subarachnoid space. Free flow of CSF was obtained confirming successful location of proper needle placement

correspondence

and 7 mg of bupivacaine with 15 mcg fentanyl was injected in subarchnoid space to achieve spinal block upto T10 level. Surgery was completed uneventfully.

Taylor's approach is a variation of the paramedian approach which is carried out at the L5-S1 interspace, the largest interlaminar interspace of the vertebral column which is least affected by osteoarthritis, degenerative

changes. Previously Jindal et al,¹ Kumkum Gupta et al² and M.Saraswat et al³ have successfully used this technique in kyphoscoliotic patients and have stressed on the necessity to teach this technique under supervision. As with any other acquired skill, the Taylor's approach also requires repeated practice which should be rehearsed on normal spines before attempting on grossly deformed spine.

REFERENCES

1. Jindal P, Chopra G, Chaudhary A, Rizvi AA, Sharma JP. Taylor's approach in an ankylosing spondylitis patient posted for percutaneous nephrolithotomy. A challenge for anesthesiologists. Saudi J Anaesth 2009;3:87-90
2. Gupta K, Rastogi B, Gupta PK, Rastogi A, Jain M, Singh VP. Subarachnoid block with Taylor's approach for surgery of lower half of the body and lower limbs: A clinical teaching study. Anesthesia: Essays and Researches; 6:38-41
3. M Saraswat, M Radhakrishnan. Spinal Anesthesia In A Patient With Kyphoscoliosis. The Internet Journal of Anesthesiology. 2001 Volume 6 Number 1.

★★★★★

Suggested changes in central venous cannulation

Nouman I. Alvi, FCARCSI and Dileep Kumar, FCPS

Department of Anaesthesia, Aga Khan University, Karachi (Pakistan); E-mail: nouman.alvi@aku.edu

Use of ultrasound (US) is standard of care these days for central venous access¹. Traditionally, a 22 or 25 gauge seeker needle (injection) was used to locate the internal jugular vein. After the introduction of US in clinical practice introducer needles are now used alone for localization and threading guide wires into central veins. In our University-hospital based Department, Arrow[®] triple lumen catheter sets are being used, containing an 18G 2.5'' (6.35 cm) needle as introducer. Approximately two thousand central lines are placed under US annually and our faculty has largely discarded the practice of using seeker needles. The depth and coordinates^{3,4} of internal jugular vein are estimated by using the calibrated view on the display screen of the ultrasound machine.

We feel that there ought to be two changes in the introducer needles; graduated markings on the shaft and a reduced length (up to 3.5 cm). They are usually 6.35 cm to 8 cm long depending on commercial makes. This length is hardly ever needed even in obese patients Figure 1. These changes will prompt anesthetists to gauge the required depth and

the introducer needle would be inserted according to calculated depth. These changes will preclude the risks of pneumothorax, brachial plexus, spinal cord and thoracic duct injuries which are known complications² of central vein cannulation using a traditional long, unmarked introducer needle.




Figure 1: Introducer needles with suggested graduated markings

REFERENCES

1. Guidance on the use of ultrasound locating devices for placing central venous catheters, National Institute for Clinical Excellence, ISBN: 1-84257-213-X, 04 October 2002
2. Chapman GA, Johnson D, Bodenham AR. Visualisation of needle position using ultrasonography. Anaesthesia 2006 Feb;61(2):148-58
3. Dietz HP, Haylen BT, Broome J. Ultrasound in the quantification of female pelvic organ prolapse. Ultrasound Obstet Gynecol. 2001 Nov;18(5):511-4.
4. Kirchmair, Lukas, Entner, Tanja MD; Kapral, Stephan MD; Mitterschiffthaler, Gottfried MD. Ultrasound Guidance for the Psoas Compartment Block: An Imaging Study. Anesth & Analg 2002 March;94(3):706-710

★★★★★