



## Effects of ultrasound-guided intraarticular botox vs. corticosteroids for shoulder osteoarthritis

Seyed Masoud Hashemi<sup>1</sup>, Seyed Mehdi Hosseini Khamene<sup>2</sup>,  
Bahram Naderi-Nabi<sup>3</sup>, Mahshid Ghasemi<sup>1</sup>

### ABSTRACT

<sup>1</sup>Department of Pain Medicine, Shahid Beheshti University of Medical Sciences, Tehran, (Iran)

<sup>2</sup>Department of Orthopedic Surgery, Shahid Beheshti University of Medical Sciences, Tehran, (Iran)

<sup>3</sup>Department of Pain Medicine, Guilan University of Medical Sciences, Tehran, (Iran)

#### Correspondence:

Dr Mahshid Ghasemi,  
Department of Anesthesiology and Pain, Taleghani Educational Hospital, Tabnak St. Velenjak Region, Chamran High Way, Tehran, (Iran); Tel: +989121548175; E-mail: Aramgol@gmail.com

**Received:** 18 May 2018

**Reviewed:** 16 Jul, 8 Aug 2018

**Corrected:** 18 Sep, 2018

**Accepted:** 18 Sep 2018

**Background:** Shoulder osteoarthritis (OA) is a painful condition in which movement of the shoulder becomes restricted. Treatment is aimed at pain reduction and maintain or improve functions. Intra-articular steroid injections have proven to be an effective and cost-effective treatment option. However, long-term use can weaken the shoulder tendons and cause histological changes. Recently, botulinum toxin has been evaluated for the treatment of the chronic joint pain. Its injection into the painful shoulder joints may inhibit the inflammatory mediators and the neuropeptide release which act on articular nociceptors and produce pain.

**Objective:** The present study compared the efficacy of ultrasound-guided intra-articular Botox and corticosteroid injections in glenohumeral joint in terms of reduction of pain scores and enhancing range of movement in patients with shoulder OA.

**Methodology:** Fifty eligible patients with shoulder OA were randomly assigned to two groups of Botox and corticosteroid (each with 25 patients). Ultrasound-guided intra-articular injections were randomly performed in all participants. Patients were evaluated in terms of effect on pre-procedure pain scores, range of abduction, internal rotation and external rotation, at 2 weeks and 12 weeks after injection. Two-way ANOVA and t-tests were utilized to analyze the data.

**Results:** The study results indicated that the injection of Botox and corticosteroid in the shoulder joint cause reduction in pain and increased range of movements of the patients with glenohumeral OA. Botox injection exerts more long-lasting effects in comparison to the corticosteroid group. Mean pain scores were lower in Botox group in comparison to the steroid group (2.75 vs. 4.24); patients in the Botox group experienced more pain reduction at week-12 and more increase in range of abduction, internal rotation and external rotation.

**Conclusion:** It is concluded that intra-articular Botox injection can be more useful than intra-articular steroid injection in terms of pain reduction and function improvement.

**Key words:** Osteoarthritis; Botulinum toxin; Pain management; Acetylcholine; Receptors, Cholinergic

**Citation:** Hashemi SM, Khamene SMH, Nabi BN, Ghasemi M. Effects of ultrasound-guided intraarticular botox vs. corticosteroids for shoulder osteoarthritis. *Anaesth Pain & Intensive Care* 2018;22(3):355-360

## INTRODUCTION

Arthritis or osteoarthritis (OA), also called joint abrasion, is a disease that can engage any joint in the human body. In this disease, the joint cartilage gradually breaks and degrades and the bones on either end of the joint that should normally slide on cartilage's smooth surface become directly in touch with one another and move about on the osteoid part of one another and this causes pain.<sup>1,2</sup> The disease is one possible cause of pain in the shoulder region, especially in the old-aged individuals. The hereditary background can also be involved in the emergence of the disease.<sup>3</sup> The primary symptoms of arthritis are shoulder pain and limitation in the range of movements. The pain is usually felt at the side of the shoulder head or the posterior upper side of the arm. The pain worsens when working and it might even appear when asleep. The patient cannot raise upper limbs completely or move them in various directions.<sup>1,3,4</sup> OA becomes more prevalent with the increase in age and radiological evidence demonstrates a prevalence rate of 94% in women and 85% in men above the age of 80. About 20% to 40% of the OA cases are symptomatic but no direct relationship has been documented between the clinical findings and the degree of the patients' performance disabilities with radiological findings.<sup>5</sup> Continuous shoulder pain lasting for a month or so has been reported in 5% of the American population for a period of a year.<sup>3,6</sup>

There are few methods for treating shoulder arthritis.<sup>4</sup> Corticosteroid injection in the joint is one common treatment method that has been proved effective in cases of intra-articular inflammation. In patients with tendonitis, as well, the injection of steroid in the biceps tendon head has also been found effective. However, steroids have been shown to fail in a great many of resistant cases and it is yet to be replaced by an appropriate alternative. In the meanwhile, steroid injections in athlete patients can cause positive doping tests and a raised blood glucose in diabetics.<sup>7</sup>

On the other hand, corticosteroids can cause atrophy of the adipose tissue and dermal changes, tendon tear and avascular necrosis. It has been shown that the patients who received intra-articular corticosteroid injection during six months before perfect arthroplasty, are more prone to postoperative infections. Face flush happens during several hours after steroids and it can last for several days. There may be suppression of the hypothalamus-pituitary-adrenal axis, though it is weak and transient. There is concern that the intra-articular injection might

cause degeneration of the joint. The reason behind such an incident might be the catabolic effect of corticosteroids or the overuse of the joint in patients whose pain has been lessened.<sup>2,4,7</sup>

Botulinum toxin is one of the neurotoxins produced by *Clostridium botulinum* bacteria. Botulinum neurotoxins are zinc dependent enzymes,<sup>8-10</sup> which reversibly block neurotransmission<sup>9</sup> by inhibiting release of neurotransmitters (the chemical signals) and disrupting neuronal communication.<sup>11</sup> There are seven botulinum serotypes (A to G), all of which inhibit acetylcholine release at the neuromuscular junction to prevent the muscle from contracting. This property enables the use of botulinum toxin in treating spasticity associated with stroke, multiple sclerosis, Parkinson's disease and cerebral palsy.<sup>12</sup> There is emerging evidence on the use of botulinum toxin for pain relief in musculoskeletal disorders.<sup>13</sup>

Previous studies have shown that botulinum injection is effective in reducing shoulder joint pain.<sup>14-20</sup> Unfortunately, there are few clinical researches regarding the non-invasive treatment of the diseases and no study has yet considered the comparison of Botox and corticosteroid injection in shoulder joint. Therefore, the current study was designed to compare the efficacy of ultrasound-guided Botox and corticosteroid injections in shoulder joint in patients with glenohumeral OA.

## METHODOLOGY

The present study was a double-blind randomized parallel-group clinical trial. Study population comprised of patients with resistant shoulder pains caused by glenohumeral joint OA.

The Institutional Ethics Committee approved the study protocol. The study was explained to participants, and an informed written consent was obtained from all patients.

Fifty patients with glenohumeral joint OA referred to Akhtar Hospital during September 2017-February 2018, were randomly assigned to either Botox or steroid groups, each containing 25 subjects.

Sample size was determined to be 50 after a pilot study on 10 individuals was performed; Considering the mean difference of the pain scores of the two groups on week two, mean pain scores of the Botox group and corticosteroid group were 2.6 and 3.3 and their standard deviation were 0.6 and 1.1, respectively. Giving proper sample size calculation formula, the overall sample was determined to be 50 subjects.

## botox vs steroid injections for shoulder osteoarthritis

$$N = \frac{(Z_{1-\beta/2} + Z_{1-\alpha/2})^2 (S_1^2 + S_2^2)}{(\mu_1 - \mu_2)^2}$$

$$N = \frac{(Z_{1-\beta/2} + Z_{1-\alpha/2})^2 (S_1^2 + S_2^2)}{(\mu_1 - \mu_2)^2}$$

$\beta = 80\% \rightarrow Z_{1-\beta} = 0.84$  and  $\alpha = 0.05 \rightarrow Z_{1-\alpha/2} = 1.96$

Sampling was performed using census method.

Inclusion criteria were age between 45-65 years, chronic painful unilateral shoulder pain lasting for more than 3 months for whom diagnosis of glenohumeral joint OA was confirmed according to American Association of Orthopedic Surgeons (AAOS) criteria, failed conservative treatment, and were not surgical candidate.

Exclusion criteria were history of arthropathic or neuropathic diseases, traumatic fractures, tendon tear, concomitant use of aminoglycoside or agents that interfere with neuromuscular junction transmission, those having already received a shoulder injection in the past 12 months; those with other established chronic shoulder disorders (for example, rheumatoid arthritis, other inflammatory polyarthropathies and OA); history of previous shoulder surgery on the affected side; history of cardiovascular, renal, hepatic or gastrointestinal disease, diabetes, coagulopathic disorders, hypertension, psychological illness or drug/alcohol abuse, pre-existing allergies, immunocompromised patients; and active infection.

Patients were randomly assigned to two Botox and corticosteroid groups. Baseline assessment was performed prior to the intervention and patients' demographic data were recorded. Freeze-dried botulinum toxin A (BTX, Type-A Company) was reconstituted immediately prior to injection, in 5 ml preservative-free sterile 0.9% normal saline (100 units/5 ml). Triamcinolone hexacetonide was also prepared as 10 mg/4 ml. All the injections were performed by an anesthesiologist, expert in musculoskeletal interventional procedures. The physician injected the affected joint using the technique of insertion of the needle parallel with respect to the transducer.

Patients were evaluated by a physician blind to the procedures at three time points: T0 (before intervention) and T2 (2 weeks after intervention) T12 (12 weeks after intervention) and pain, and range of motion during internal rotation, external rotation, and abduction were measured for all patients. Any potential side effects was also noted and recorded.

Patients, outcome investigators and the statistician were blinded in this study.

All statistical analyses were performed using SPSS version 19.0 for Windows (SPSS Inc, Chicago, IL, USA). An alpha level  $< 0.05$  was considered to be statistically significant. Kolmogorov-Smirnov test was utilized to evaluate the normality of the data distribution.

### RESULTS:

The average age of the study subjects was  $52.98 \pm 11.7$ . Twenty four patients were male and 26 patients were female and there was no significant difference between the two groups in terms of age and gender ( $p > 0.05$ ).

#### VAS:

The results of Kolmogorov-Smirnov test signified the normality of data distribution ( $p > 0.05$ ). The results of t-test indicated that there was a significant difference between the two groups before the intervention in terms of VAS ( $p > 0.05$ ). The total mean score of the pain was lower in Botox group than in corticosteroid group e.g. 2.75 vs. 4.24 respectively.

Bonferroni's follow-up test was used to evaluate the differences during follow-up (pre-injection, week-2 and week-12). The differences were significant in the course of the time, meaning that both of the drugs resulted in pain reduction during study. There was no significant difference between the two groups pre-injection and at week-2, but the difference between the two groups was found to be significant at week-12; the Botox group having experienced a statistically significant pain relief ( $p < 0.05$ ). Results are shown in Figure 1.

#### ROM:

The results of the Kolmogorov-Smirnov test are suggestive of the data distribution normality ( $p > 0.05$ ). The results of the t-test showed that there was no significant difference between the two groups in terms of range of abduction, internal rotation and external rotation before injection ( $p > 0.05$ ).

**Abduction:** The study findings demonstrated that the main effect of both the groups ( $F_{1, 48} = 804.381$ ,  $p < 0.05$ ) was significant in terms of the range of abduction at week-2 and week-12; the difference of effect compared within the groups was not statistically significant (Figure 2).

**Internal Rotation:** The findings showed that the main effect on range of internal rotation in both of the groups at pre-injection time, and the change in

## botox vs steroid injections for shoulder osteoarthritis

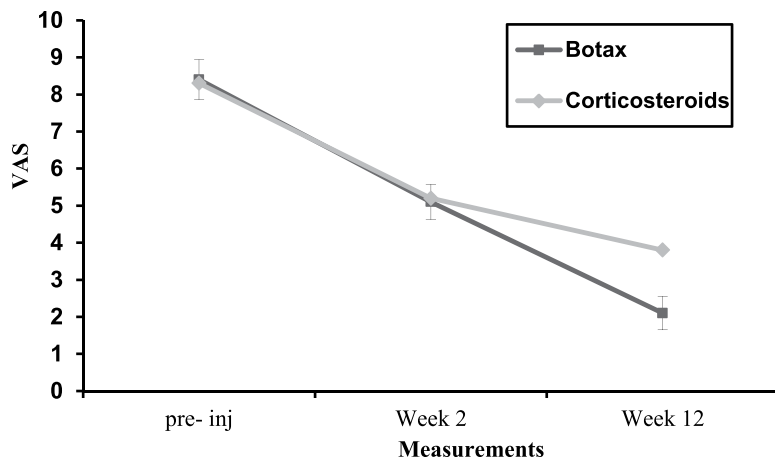


Figure 1: Comparison of VAS score between two groups at different time periods

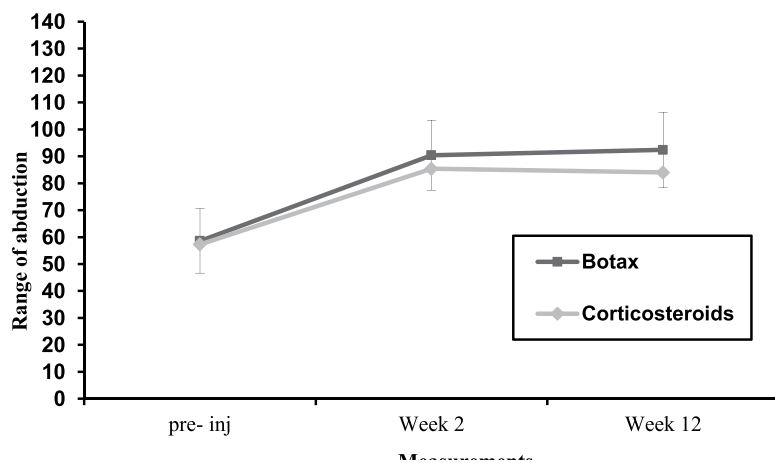


Figure 2: Comparison of range of abduction between two groups at different time periods

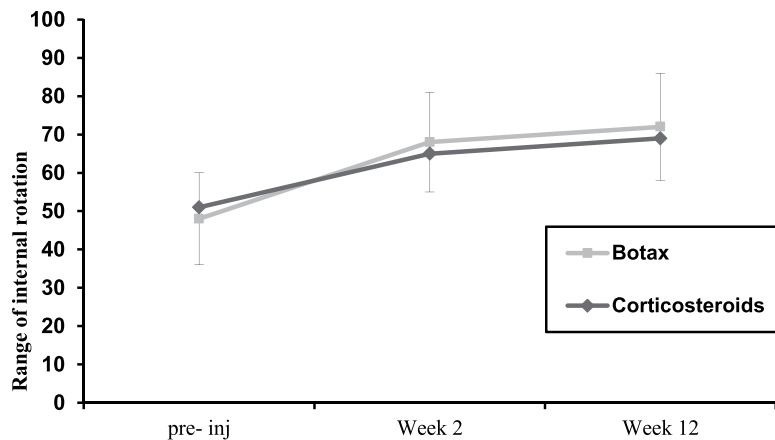


Figure 3: Comparison of range of internal rotation between two groups at different time periods

the range at week-2 and week-12, did not change statistically significantly (Figure 3).

**External Rotation:** Results of the variance analysis indicated that the main effect at the week-2 was statistically significant ( $F_{2, 48} = 25.855$ ,  $p < 0.05$ ) but the main effect of the week-12 and inter-group differences were not statistically significant (Figure 4).

## DISCUSSION

The present study aimed at comparing the effects of ultrasound-guided intra-articular Botox and corticosteroids injection in the shoulder joint in patients with glenohumeral OA. The study results indicated that the injection of both Botox and corticosteroid in the glenohumeral joint brings about a reduction in the pain and improves the range of movements of the patients with glenohumeral OA. Although Botox injection's effect lasted for a longer period of time in such a manner that the total mean of the pain scores was lower in Botox group as compared to the steroid group (2.75 in contrast to 4.24) and the Botox group experienced a larger reduction in pain in week-12. Also, the other findings of the study were reflective of the idea that the Botox injection leads to an increase in abduction, internal rotation and external rotation of the patients. The study findings are consistent with the results obtained in several other studies.<sup>8-13,19</sup> For example, the results obtained by Boon et al.<sup>14</sup> indicated that Botox group experienced a significant pain reduction as compared to the control group; moreover, the patients from the Botox group were found with increased improvement of range of movements in the shoulder region in comparison to the control group. They concluded that the use of Botox in contrast to steroid or placebo treatments has a better treatment effects on the shoulder joint. Singh et al.<sup>17</sup> came to the conclusion that

the prior studies are suggestive of effectiveness of

## botox vs steroid injections for shoulder osteoarthritis

Botox injection in improving pain in patients with frozen shoulders but that the results have to be more cautiously interpreted due to the scarcity of the researches in this regard. However, generally, it seems that Botox can decrease shoulder pain due to arthritis and spastic hemiplegia. Nicol et al.<sup>16</sup> investigated the effect of botulinium toxin injection in treatment of neck and shoulder myofascial pains. Their findings indicated that intra-articular Botox injection causes a significant improvement in the pain scores at week-12 as compared to the placebo group. They attributed this effect of Botox to its antinociceptive effects. They concluded that the direct injection of Botox inside the painful muscles brings about an improvement in the pain score as well as the quality of life of the patients for such a reason as decreasing the inflammation and spasm and possibly for its antinociceptive effects. Singh et al.<sup>21</sup> showed the success of intra-articular injection of Botox in a recent study and emphasized on its antinociceptive effect in patients with resistant arthroplasty pains in such a way that it was concluded that a considerable improvement comes about in the pains experienced after the shoulder and knee arthroplasty after a week of intra-articular injection and that there is a need for repeated injections in resistant cases. In another study by Sun et al.,<sup>22</sup> Botox and hyaluronic acid injections inside the ankle joint were compared. In this comparison, Botox could act in line with pain control and functioning improvement like hyaluronic acid. It was concluded that there was no significant difference between Botox and hyaluronic acid in terms of the pace of the pain-relieving effects in week 2 and the duration of the effect in week 6. In regard of the elucidation of the present study's finding, it can be stated that Type-A botulin neurotoxin attaches to the receptors in cholinergic nerve membrane and enters the cytoplasm of the neural terminals wherein it can change the exocytose of the cholinergic

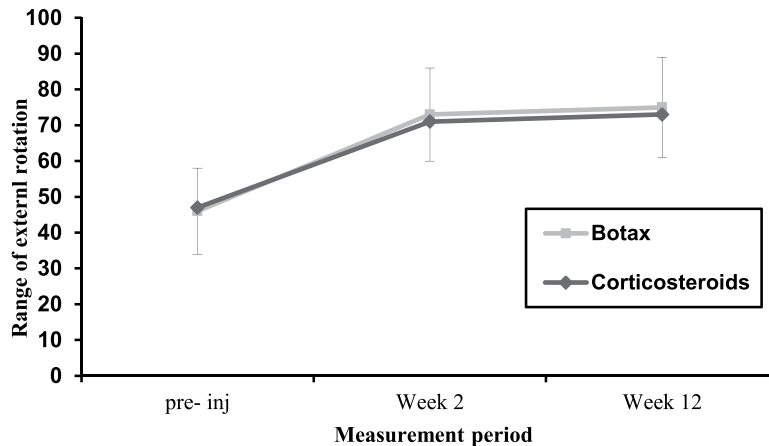


Figure 1: Comparison of VAS score between two groups at different time periods

vesicles and leads to the mitigation of their nervous activity through chemical reactions and muscular contractions.<sup>9,13,18,23-25</sup> Injection of type-A botulinum toxin is followed by an independent anti-coagulation effect.<sup>19</sup> Furthermore, its anticholinergic effects have been well documented. Such a dual action has also been observed in studies on cervical dystonia<sup>20</sup> and headache.<sup>26</sup> These pain-relieving effects are possibly due to the curbing of the neurogenic inflammations,<sup>24</sup> that result in localized edema through CGRP and P-matter and deprivation of glutamate release.<sup>18</sup> In a review research performed recently by RCTs, the analgesic effects of BoNT/A were confirmed in osteoarthritic pains in patients, including tennis elbow pains, backache, temporomandibular joint pains, carpal tunnel syndrome.<sup>21</sup>

Results of the current study provide the reader with evidence regarding the better analgesic effects and more improvement in the range of movements in patients with glenohumeral osteoarthritis with Botox injection. So, it is suggested that Botox injection can be useful in terms of its favorable therapeutic effects.

**Conflict of interest:** Nil declared by the authors

**Author contribution:** All authors took equal part in the study and manuscript preparation

REFERENCES

1. Sharma L. Osteoarthritis year in review 2015: clinical. *Osteoarthritis and cartilage*. 2016;24(1):36-48. [PubMed] [Free full text] doi: 10.1016/j.joca.2015.07.026.
2. Allen KD, Golightly YM. State of the evidence. *Curr Opin Rheumatol*. 2015 May;27(3):276-83. doi: 10.1097/BOR.000000000000161.. [PubMed] [Free full text]
3. Bjelle A. Epidemiology of shoulder problems. *Baillieres clin rheumatol*. 1989;3(3):437-51. [PubMed] doi: 10.1016/S0950-3579(89)80003-2
4. Babatunde OO, Jordan JL, Van der Windt DA, Hill JC, Foster NE, Protheroe J. Effective treatment options for musculoskeletal pain in primary care: A systematic overview of current evidence. *PLoS One*. 2017 Jun 12;22(6):e0178621. doi: 10.1371/journal.pone.0178621. [PubMed] [Free full text]
5. Brian J. Krabak, Norman L. Banks, Ed. Adhesive Capsulitis, in *Essentials of physical medicine and rehabilitation*. 2 ed: Philadelphia; 2008.
6. Plan and operation of the Third National Health and Nutrition Examination Survey, 1988-94. National Center for Health Statistics. *Vital Health Stat* 1(32). 1994. [Free full text]
7. Rezasoltani Z, Najafi S, Azizi S, Forough B, Maleki N, Fateh H. The comparison of shock wave therapy and corticosteroid injection on the treatment of plantar fasciitis. *J Army Univ Med Sci*. 2013;11(1):53-60. [Free full text]
8. Wissel J, Müller J, Dressnandt J, Heinen F, Naumann M, Topka H, et al. Management of spasticity associated pain with botulinum toxin A. *J Pain Symptom Manage*. 2000;20(1):44-9. [PubMed] [Free full text] DOI: [https://doi.org/10.1016/S0885-3924\(00\)00146-9](https://doi.org/10.1016/S0885-3924(00)00146-9) Setter PE. Therapeutic use of botulinum toxins: background and history. *Clin J Pain*. 2002;18(6 Suppl):S119-24. [PubMed]
9. Simpson K. Individual choice of opioids and formulations: strategies to achieve the optimum for the patient. *Clin Rheumatol*. 2002;21(Suppl 1):S5-S8. [PubMed]
10. Park J, Park HJ. Botulinum Toxin for the Treatment of Neuropathic Pain. *Toxins*. 2017;9(9):260. [PubMed] [Free full text] DOI: 10.3390/toxins9090260
11. Sandrini G, De Icco R, Tassorelli C, Smania N, Tamburin S. Botulinum neurotoxin type A for the treatment of pain: not just in migraine and trigeminal neuralgia. *J Headache Pain*. 2017 Dec;18(1):38. doi: 10.1186/s10194-017-0744-z. [PubMed] [Free full text]
12. Ranoux D, Attal N, Morain F, Bouhassira D. Botulinum toxin type A induces direct analgesic effects in chronic neuropathic pain. *Ann Neurol*. 2008;64(3):274-83. [PubMed] DOI: 10.1002/ana.21427
13. de Maio, Mauricio, Rzany, Berthold. *Botulinum Toxin in Aesthetic Medicine*. Springer; 2015. p. 1089-106. [Free full text]
14. Maund E, Craig D, Suekarran S, Neilson A, Wright K, Brealey S, et al. Management of frozen shoulder: a systematic review and cost-effectiveness analysis. *Health Technol Assess*. 2012;16(11):1. [Free full text] doi: <https://doi.org/10.3310/hta16110>
15. Nicol AL, Wu II, Ferrante FM. Botulinum toxin type a injections for cervical and shoulder girdle myofascial pain using an enriched protocol design. *Anesth Analg*. 2014;118(6):1326. [PubMed] [Free full text] DOI: 10.1213/ANE.000000000000192 Singh JA. Efficacy of long-term effect and repeat intraarticular botulinum toxin in patients with painful total joint arthroplasty: a retrospective study. *Br J Med Res*. 2014;4(1):139-148. [PubMed] [Free full text] doi: 10.9734/BJMMR/2014/4897
16. Cui M, Li Z, You S, Khanijou S, Aoki K, editors. Mechanisms of the antinociceptive effect of subcutaneous BOTOX (R): Inhibition of peripheral and central nociceptive processing. *Naunyn-Schmiedeberg's Archives of Pharmacology*; 2002: Springer-Verlag 175 Fifth Ave, New York, NY 10010 USA.
17. Jabbari B. Botulinum neurotoxins in the treatment of refractory pain. *Nat Clin Pract Neurol*. 2008;4(12):676-685. [PubMed] DOI: 10.1038/ncp-neuro0948
18. Jankovic J, Schwartz K. Botulinum toxin injections for cervical dystonia. *Neurology*. 1990 Feb;40(2):277-80. [PubMed]
19. Singh JA, Fitzgerald PM. Botulinum toxin for shoulder pain: a cochrane systematic review. *The Journal of rheumatology*. 2011;38(3):409-18. [PubMed] DOI: 10.3899/jrheum.101081
20. Sun S-F, Hsu C-W, Lin H-S, Chou Y-J, Chen J-Y, Wang J-L. Efficacy of intraarticular botulinum toxin A and intraarticular hyaluronate plus rehabilitation exercise in patients with unilateral ankle osteoarthritis: a randomized controlled trial. *Journal of Foot and Ankle Research*. 2014;7(1):9. [Free full text] doi: 10.1186/1757-1146-7-9
21. Mahler S, editor, *Safety of biologics therapy: Monoclonal antibodies, cytokines, fusion proteins, hormones, enzymes, coagulation proteins, vaccines, botulinum toxins. mAbs*; 2017: Taylor & Francis.
22. Meng J, Wang J, Lawrence G, Dolly JO. Synaptobrevin I mediates exocytosis of CGRP from sensory neurons and inhibition by botulinum toxins reflects their anti-nociceptive potential. *J Cell Sci*. 2007;120(16):2864-74. [PubMed] [Free full text] doi: 10.1242/jcs.012211
23. Shukla D, Sreedhar SK, Rastogi V. A Comparative Study of Botulinum Toxin: A with Triamcinolone Compared to Triamcinolone alone in the treatment of Osteoarthritis of Knee. *Anesth Essays Res*. 2018;12(1):47-49. [PubMed] [Free full text] DOI: 10.4103/aer.AER\_210\_17
24. Göbel H, Heinze A, Heinze-Kuhn K, Jost W. Evidence-based medicine: botulinum toxin A in migraine and tension-type headache. *J Neurol*. 2001;248(1):134-18. [PubMed]

