

## CASE REPORT

## REGIONAL ANESTHESIA

# The role of continuous popliteal sciatic block in a patient with acute on chronic limb-threatening ischemia: a case report

Aida R. Tantri <sup>1</sup>, Lawrence <sup>2\*</sup>

**Authors Affiliation:**

1. Aida R. Tantri, Department of Anesthesiology and Intensive Care, Faculty of Medicine, Universitas Indonesia, Dr. Cipto Mangunkusumo Hospital, Jakarta, Indonesia; E-mail: [aidatantri@gmail.com](mailto:aidatantri@gmail.com)
2. Lawrence, Department of Anesthesiology and Intensive Care, Faculty of Medicine, Universitas Indonesia, Dr. Cipto Mangunkusumo Hospital, Jakarta, Indonesia; E-mail: [lawrence@ui.ac.id](mailto:lawrence@ui.ac.id)

**Correspondence:** Lawrence; E-mail: [lawrence@ui.ac.id](mailto:lawrence@ui.ac.id); Phone: .6281382121085

## ABSTRACT

Treating ischemic pain (IP) is challenging because of complex mechanisms involved in its pathogenesis. We report a case of pain management in a patient with acute on chronic limb-threatening ischemia (CLTI) treated with continuous popliteal sciatic block (CPSB). Microcirculation was measured using Near-Infrared Spectroscopy (NIRS). The patient was a 44-year-old male with acute exacerbation of CLTI of left leg. Excruciating pain was described as being stabbed in the left toe with burning sensation radiating to ankle (VAS score 9-10), 3 to 4 times a day with duration of 30 to 60 min each episode. CT Angiography showed wide arterial occlusions and thrombi in veins of left lower limb. ABI was 0,71. He was on heparin so we decided to do CPSB with patient controlled regional analgesia (PCRA) pump of ropivacaine 0.375%. Before catheter insertion, NIRS was measured on dorsum pedis. SrO<sub>2</sub> increased from 24 to 32% within 30 min after initial bolus. Episodes of severe pain still felt with only little relief when pressing PCRA pump. Daily chart showed increasing ropivacaine utilization with discrepancy between attempted and given dose. SrO<sub>2</sub> fluctuated between 25 to 32%. On the third day evaluation, we switched to multimodal analgesia. However, pain attacks increased in frequency, intensity and duration. Ischemic area in foot expanded rapidly. High dose methyl prednisolone was initiated. Amputation was suggested but refused by the patient.

Peripheral nerve block does not completely block ischemic pain, despite adequate motor block. However, it may be beneficial in cases of CLTI by maintaining blood flow, thus inhibiting the progression of ischemia. In this patient, it is evident that upon cessation of CPSB, the condition of the leg deteriorated rapidly.

**Keywords:** Chronic limb-threatening ischemia, Continuous popliteal sciatic block, Ischemic Pain

**Citation:** Tantri AR, Lawrence. The role of continuous popliteal sciatic block in a patient with acute on chronic limb-threatening ischemia: a case report. *Anaesth. pain intensive care* 2024;28(3):585–587; DOI: [10.35975/apic.v28i3.2454](https://doi.org/10.35975/apic.v28i3.2454)

**Received:** March 23, 2024; **Reviewed:** April 27, 2024; **Accepted:** April 27, 2024

## 1. INTRODUCTION

The mechanisms involved in the pathogenesis of ischemic pain are complex, and still not completely understood, making its management difficult. The literature on peripheral nerve blocks to relieve ischemic pain is divided between proponents of peripheral nerve blocks and those who are in the opposite camp. However, regional anesthesia with peripheral nerve blocks is known to increase blood flow to the innervated

tissue possibly due to partial block of the sympathetic nerve supply to that area.<sup>1</sup> We report a case of pain management in a patient with acute on chronic limb-threatening ischemia (ACLTI) treated with continuous popliteal sciatic block, where microcirculation was also monitored using Near-Infrared Spectroscopy (NIRS) parameters. This case report is expected to be an input on the role of peripheral nerve blocks in management of

excruciating pain due to acute on chronic limb-threatening ischemia.

## 2. CASE REPORT

A 44-year-old male patient with ACLTI on his left foot was referred by the vascular surgeon to the acute pain service (APS) team. Pain was described as being stabbing by knife in character in his left toe and feeling of heat which radiated to the ankle area. VAS score was 9-10. Pain attacks occurred 3 to 4 times a day, each lasting for half to one hour. The patient remained calm when not in an episode of CCLTI with a VAS score of 2-3.

His labs showed hyponatremia (121) and mild elevation of serum transaminases. Renal function was normal. Ankle-brachial index (ABI) was 0.71. ABI is a non-invasive tool for the assessment of vascular status. It consists of the ratio between the systolic blood pressure of the lower extremity, specifically the ankle, and the upper extremity. CT angiography showed arterial occlusion starting from superficial femoral and profunda femoris artery to left dorsalis pedis artery with thrombosis in the left femoro-popliteal vein.

On admission, the patient was on heparinization therapy 25,000 iu/24 h. His aPTT was 1.1x. It was decided to use patient controlled regional analgesia on the popliteal sciatic nerve. Before catheter insertion, we measured the NIRS values at 3 points on the posterior upper thigh, lateral cruris and dorsum pedis with values of 54, 30 and 24.

The initial bolus was Ropivacaine 0.375% 20 cc, pain subsided to VAS 0 and NIRS score increased from 24 to 32 within 30 min after bolus. The patient was then given

a regimen of inj. ropivacaine 0.2%, continuous @ 6 mL/h, PCA dose 6 mL and lock out interval of 20 min.

During the use of PCRA, the patient still felt pain, the intensity of which decreased when pressing the PCRA. The patient also complained of leg heaviness. The PCRA utilization chart showed high ropivacaine utilization with discrepancy between attempted and given dose. NIRS in the dorsum pedis area was measured again on the third day with values of 25-31.

The patient was referred to the Rheumatology department with suspicion of vasculitis. After several evaluations and considerations, we decided to change the analgesia strategy and remove the continuous peripheral block catheter (after 3 days of PCRA use). Four hours after the catheter was removed, the patient began to experience severe pain episodes of longer than usual duration. The attacks became more frequent and with longer duration. The foot looked hyperemic and the ischemic area was widespread.

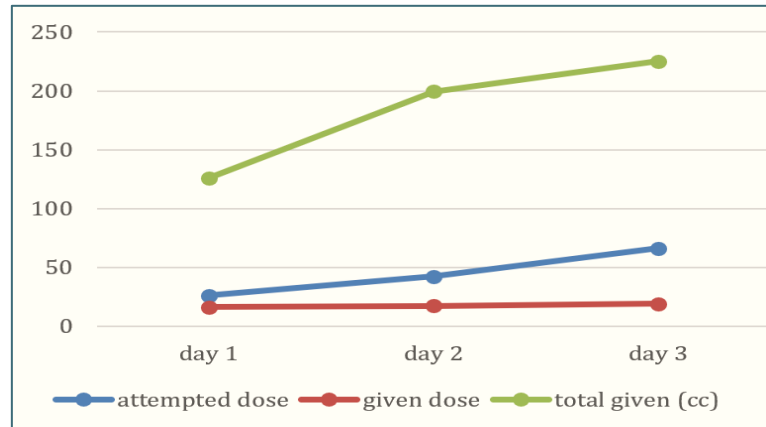


Figure 1: PCRA daily chart

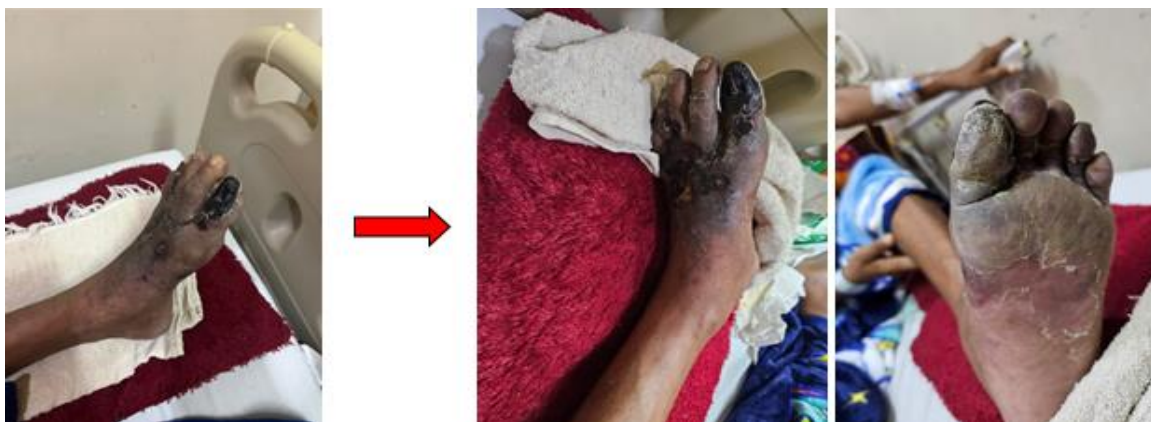

Figure 2: Changes in foot 12 hours after CPSB discontinuation

The rheumatologist started high doses of methylprednisolone. For pain management, the patient received tramadol 3x50 mg, gabapentin 3x300 mg and paracetamol 3x1 g. Immediate release morphine 10 mg was added when the pain was very severe. The patient was advised amputation by the vascular surgeon but he refused.

### 3. DISCUSSION

PCRA with ropivacaine 0.2% reduced, but did not eliminate pain in this patient. Pain attacks were still persistent despite partial motor block. The NIRS score showed improvement within 30 min after the first ropivacaine bolus, although it was not significant and fluctuated. On the third day of catheter insertion, the NIRS score was still in the same range. The patient did not like the feeling of weakness in the limbs so we decided to discontinue the use of PCRA and change the analgesia strategy. However, after PCRA was stopped, the pain attacks increased in intensity, duration and frequency. There was an expansion of the ischemia-affected area of the foot.

Kucera and Boezaart, reported two cases, where regional analgesia did not relieve ischemic pain despite adequate motor and sensory block.<sup>1</sup> Munk-Andersen and Lastrup, reported a case of post-surgical acute compartment syndrome (ACS), who was diagnosed with pain despite receiving ropivacaine 0.2% PCRA.<sup>2</sup> They stated that ischemic pain is mediated by A-β fibers, so that low concentrations of local anesthetics do not block ischemic pain in ACS. On the other hand, Souza et al, reported the successful use of continuous popliteal sciatic block in relieving the pain of CLTI patients.<sup>3</sup>

Regional anesthesia causes vasodilation due to sympathetic block thus increasing blood flow to the innervated area. Several studies have shown an increase in tissue saturation after peripheral block in healthy tissue.<sup>4,5</sup>

The rapid progression of ischemia in this patient illustrates the difficulty of treating CLTI. Continuous popliteal sciatic block in this patient may have helped slow down the progress. Reports vary in results, that suggests that peripheral block does not consistently relieve ischemic pain,<sup>1-3, 6, 7</sup> we believe that peripheral block has a positive effect on ischemic pain, either through analgesia, anti-inflammation or increased regional blood flow.

### 4. CONCLUSIONS

Our case report supports the evidence that ischemic pain is not fully blocked by peripheral nerve block. However peripheral nerve block maybe useful for maintaining blood flow to already ischemic tissue. Careful dosing and infusion strategies are vital to prevent systemic effects while providing targeted pain relief.

#### 5. Ethical considerations

Approval was obtained from the Ethical Committee of Faculty of Medicine, Universitas Indonesia, Dr. Cipto Mangunkusumo Hospital, Jakarta, Indonesia. Written permission was obtained from the patient to publish this case report as an academic service.

#### 6. Authors' contribution

Both authors took part in the conduct of this case and preparation of this manuscript.

### 7. REFERENCES

1. Kucera TJ, Boezaart AP. Regional anesthesia does not consistently block ischemic pain: two further cases and a review of the literature. *Pain Med.* 2014;15(2):316-9. [PubMed] DOI: [10.1111/pme.12235](https://doi.org/10.1111/pme.12235)
2. Munk-Andersen H, Lastrup TK. Compartment syndrome diagnosed in due time by breakthrough pain despite continuous peripheral nerve block. *Acta Anaesthesiol Scand.* 2013;57(10):1328-30. [PubMed] DOI: [10.1111/aas.12187](https://doi.org/10.1111/aas.12187)
3. D'Souza RS, Shen S, Ojukwu F, Gazelka HM, Pulos BP. Partnering with Palliative Care: A Case Report of Severe Pain in Critical Limb Ischemia Treated Successfully with a Continuous Popliteal Nerve Catheter. *Case Rep Anesthesiol.* 2020;2020:1054521. [PubMed] DOI: [10.1155/2020/1054521](https://doi.org/10.1155/2020/1054521)
4. Lima A, Galvin E, Bommel JV, Bakker J. Effects of peripheral vasodilation induced by regional anaesthesia blocks on resting tissue oxygenation values. *Crit Care.* 2009;13(Suppl 1):P237. DOI: [10.1186/cc7401](https://doi.org/10.1186/cc7401)
5. Macfarlane AJR, Vlassakov K, Elkassabany N. Regional anesthesia for vascular surgery: does the anesthetic choice influence outcome? *Curr Opin Anaesthesiol.* 2019;32(5):690-6. [PubMed] DOI: [10.1097/ACO.0000000000000781](https://doi.org/10.1097/ACO.0000000000000781)
6. Lakkaraju U, Gurram R. Role of ultrasound guided continuous sciatic nerve blocks in a complicated case of vasopressor induced lower limb ischemic pain. *Indian J Pain.* 2019;33(2):103-5. DOI: [10.4103/ijpn.ijpn\\_68\\_18](https://doi.org/10.4103/ijpn.ijpn_68_18)
7. Fernandes HDS, Ximenes JLS, Taguchi PK, Espada EB, Gouvêa Á L, Vieira JE, et al. Continuous peripheral nerve block for in-patients with lower limb ischemic pain. *Clinics (Sao Paulo).* 2021;76:e2805. [PubMed] DOI: [10.6061/clinics/2021/e2805](https://doi.org/10.6061/clinics/2021/e2805)