

ORIGINAL RESEARCH

REGIONAL ANESTHESIA

Efficacy and safety of single-shot erector spinae plane block for perioperative analgesia in pediatric surgery: a systematic review and meta-analysis

Mahendratama P. Adhi,¹ Rusmin B. Syukur,² Lucky Andriyanto,³ Elizeus Hanindito,⁴ Arie Utariani⁵

Author affiliations:

1. Mahendratama P. Adhi, Department of Anesthesiology and Reanimation, Faculty of Medicine, Airlangga University, Surabaya, Indonesia; E-mail: mahendratama.adhi@ulm.ac.id; ORCID: {0000-0002-1308-3330}
2. Rusmin B. Syukur, Department of Anesthesiology and Reanimation, Faculty of Medicine, Airlangga University, Surabaya, Indonesia; E-mail: rusminsyukur@unhas.ac.id; ORCID: {0000-0001-8019-7228}
3. Lucky Andriyanto, Department of Anesthesiology and Reanimation, Faculty of Medicine, Airlangga University, Surabaya, Indonesia; E-mail: lky.anest@gmail.com; ORCID: {0000-0003-3618-5433}
4. Elizeus Hanindito, Department of Anesthesiology and Reanimation, Faculty of Medicine, Airlangga University, Surabaya, Indonesia; E-mail: elizeushanindito@gmail.com; ORCID: {0000-0003-0061-8372}
5. Arie Utariani, Department of Anesthesiology and Reanimation, Faculty of Medicine, Airlangga University, Surabaya, Indonesia; E-mail: arieutariani299@gmail.com; ORCID: {0000-0002-1438-2447}

Correspondence: Mahendratama P. Adhi; E-mail: mahendratama.adhi@ulm.ac.id; Phone: +62511-3262392; Mobile: +62 81242900096

ABSTRACT

Background and Objective: Since its introduction in 2016, ultrasound-guided ESPB has been utilized in various surgical contexts. Numerous case reports and studies have suggested that ESPB in pediatrics can offer perioperative analgesia, but its clinical effects have remained controversial. Therefore, this review aims to comprehensively analyze the efficacy and safety of single-shot ESPB in pediatrics.

Methodology: The literature search was electronically conducted in the Cochrane Library, PubMed, and Google Scholar databases, covering data available until December 2022. This meta-analysis encompassed English-language RCT that compared preoperative single-shot ESPB with a control group (no block or sham block) in pediatric patients (age < 18 y). The primary outcomes encompassed total intra and postoperative opioid consumption and the time first to rescue analgesia. Secondary outcomes comprised 24-hour postoperative pain scores, the incidence of PONV, and complications linked to local anesthesia and the ESPB procedure.

Results: The analysis incorporated six RCTs, encompassing 320 samples. Single-shot ESPB demonstrated a reduction in intraoperative opioid consumption (MD: -0.54; 95% CI [-0.97, -0.11], I² = 97%, P = 0.01, very low-quality certainty of evidence), 24-hour postoperative opioid consumption (MD: -0.12; 95% CI [-0.21, -0.02], I² = 93%, P = 0.02, low quality certainty of evidence), and an extension in the time to the first rescue analgesia requirement (MD: 3.38; 95% CI [2.38, 4.39], I² = 96%, P < 0.00001, very low-quality certainty of evidence). The ESPB group exhibited reduced postoperative pain scores at 0, 1, 4, and 6 h (P < 0.05); however, no significant differences were observed compared to the control group at 2, 12, and 24 h. The incidence of PONV was also significantly lower in the ESPB group (P = 0.04). Encouragingly, all six RCTs reported no instances of complications associated with local anesthesia and the ESPB procedure.

Conclusion: This meta-analysis showed that ultrasound-guided single-shot ESPB in pediatrics diminished both intraoperative and postoperative opioid needs and also led to a decrease in occurrences of PONV. Furthermore, it effectively alleviated postoperative pain while maintaining safety against the potential risks of local anesthetic toxicity and complications linked to the ESPB procedure.

Abbreviations: CI - Confidence interval; ESPB - Erector spinae plane block; MD - Mean difference; PONV - Postoperative nausea and vomiting; RCT - Randomized controlled trial

Key words: Anesthesia, Regional; Erector Spinae Plane Block; Opioid; Pediatric; Pain, Perioperative; ESPB

Citation: Adhi MP, Syukur RB, Andriyanto L, Hanindito E, Utariani A. Efficacy and safety of single-shot erector spinae plane block for perioperative analgesia in pediatric surgery: A systematic review and meta-analysis. *Anaesth. pain intensive care* 2024;28(2):291–301; DOI: [10.35975/apic.v28i2.2437](https://doi.org/10.35975/apic.v28i2.2437)

Received: August 20, 2023; **Revised:** January 13, 2024; **Accepted:** January 21, 2024

1. INTRODUCTION

Postoperative pain is common among pediatric patients, affecting more than 85%.¹ A comprehensive survey revealed that 40% of these young patients endure postoperative pain of moderate to severe intensity, and a staggering 75% of them do not receive adequate analgesia.² This deficiency in pain management can lead to maladaptive behavioral changes, heightened reliance on analgesics, delayed postoperative recovery, and prolonged hospital stays.¹ The implementation of a preventive analgesia approach for pediatric pain management holds the potential to offer optimal analgesic quality while also diminishing postoperative pain and analgesic consumption.

In the aspect of managing moderate to severe pain in pediatric cases, opioids are frequently employed. Despite providing effective pain relief, opioids have side effects, including pruritus, nausea, vomiting, urinary retention, constipation, ileus, respiratory depression, and opioid-induced hyperalgesia.^{3,4} A potential measure to address these concerns is the reduction of opioid usage during the perioperative period.⁴ This measure is consistent with the Enhanced Recovery After Surgery (ERAS) protocols in pediatrics, which advocate for a multimodal analgesia approach to decrease intraoperative and postoperative opioid demands, hasten recovery, and mitigate complications.⁵

Incorporating regional anesthesia within the framework of multimodal analgesia during general anesthesia offers numerous advantages. Regional anesthesia can potentially diminish or perhaps eliminate the impacts of the surgical stress response, ensuring efficient postoperative pain alleviation. Furthermore, this approach can minimize the requirement for intravenous or volatile anesthetic agents during surgery, resulting in a faster emergence from anesthesia and earlier extubation.⁵

Over the past decade, the use of regional anesthesia, particularly block anesthesia, has notably increased. The evolution of block anesthesia techniques is closely intertwined with advancements in ultrasound imaging technology, offering enhanced safety, efficacy, efficiency, and ease of application.⁶ This progress has

brought forth techniques such as the erector spine plane block (ESPB), which has gained popularity. Since its

inception by Forero,⁷ the ESPB method has found applications in a range of surgeries, including those encompassing pediatric cases. The first publication on the application of ESPB in pediatrics was presented in 2017 when Munoz et al. reported that ESPB yielded optimal pain relief for up to 32 h after chest wall tumor resection.⁸ In a retrospective study encompassing 164 pediatric patients undergoing diverse surgical procedures, it was observed that over 70% of ESPB cases achieved effective intraoperative pain management.⁹

Several randomized controlled trials (RCTs) have stated that preoperative single-shot ESPB in pediatrics can lead to reductions in both intra and postoperative opioid requirements, along with lowered postoperative pain scores.^{10–12} Another study indicated that although ESPB can decrease postoperative opioid consumption, there is no significant divergence in pain scores within 24 h following surgery compared to the control group.¹³

Based on the above explanation, this study aimed to evaluate the effectiveness and safety of single-shot ESPB as a perioperative analgesic method in pediatrics. The primary outcomes encompass the perioperative pain-relieving effectiveness of single-shot ESPB, assessed through measurements of intra and postoperative opioid use, as well as the time taken until the first instance of supplementary analgesia. Secondary outcomes involve pain scores within 24 h post-surgery, postoperative nausea and vomiting (PONV) occurrences, and any adverse effects of local anesthesia and the ESPB procedure.

2. METHODOLOGY

This study aligned with the Preferred Reporting Items for Systematic Reviews and Meta-analyses (PRISMA) guidelines.¹⁴ The process involved an electronic literature search across the Cochrane Library, PubMed, and Google Scholar databases, utilizing specific keywords ("Erector spinae plane block" OR "ESP block" OR "ESPB") AND ("pediatric" OR "children" OR "neonate" OR "infant" OR "adolescent"), covering the timeframe up to December 31, 2022.

Table 1: Characteristics of the included RCTs

Author & Year	Type of surgery	Type of ESPB & local anesthetic	Comparator	Sample size (ESPB /control)	Intraoperative opioid	Postoperative analgesia	Postoperative rescue analgesia
Kaushal, 2019	Cardiac surgeries through a midline sternotomy	Bilateral ESPB at T3 level, 1.5 mL/kg ropivacaine 0.2% on each side	No block	40/40	Inj. fentanyl IV	Acetaminophen 15 mg/kg/8 h IV	fentanyl 0.5 -1 mcg/kg IV when MOPS score ≥ 4
Mostafa, 2019	Splenectomy	Bilateral ESPB at T7 level, 0.3 mL/kg bupivacaine 0.25% on each side	Sham block	30/30	Inj. fentanyl IV	Diclofenac suppository 25 mg/8 h	Paracetamol 15 mg/kg IV when CHEOPS score > 6
Singh, 2020	Lower abdominal surgeries	Bilateral ESPB at L1 level, 0.5 mL/kg bupivacaine 0.25% on each side	No block	20/20	NA	Single dose acetaminophen 15 mg/kg IV	Morphine 0.05 mg/kg IV when FLACC score ≥ 4
Abduallah, 2022	Hip surgery	Unilateral ESPB at L1 level, 0.4 mL/kg bupivacaine 0.25%	Sham block	20/20	Inj. fentanyl IV	Acetaminophen 15 mg/kg/6 h IV	Morphine 0.05 mg/kg IV when CHEOPS score > 6
Karacaer, 2022	Cardiac surgeries through a midline sternotomy	Bilateral ESPB at T5 level, 0.5 mL/kg bupivacaine 0.25% on each side	No block	20/20	Inj. fentanyl IV	Acetaminophen 15 mg/kg/6 h IV	Morphine 0.05 mg/kg IV when MOPS score ≥ 4
Yuan, 2022	Thoracoscopic lung lesion resection	Unilateral ESPB at T4 level, 0.5 mL/kg levobupivacaine 0.25%	No block	30/30	Inj. remifentanil IV	Oral acetaminophen 15 mg/kg/6 h	Sufentanil 0.05-0.1 $\mu\text{g}/\text{kg}$ IV when FLACC score > 4

Abbreviations: CHEOPS, Children's Hospital of Eastern Ontario Pain Scale; ESPB, erector spinae plane block; FLACC, Face, Legs, Activity, Cry and Consolability; L, lumbar; MOPS, Modified Objective Pain Scale; NA, not available; T, thoracic

2.1. Study selection

Two reviewers (MA and RS) screened articles based upon the title and the abstract evaluation. The analysis included studies that met the PICOS (Population, Intervention, Comparison, Outcome, Studies) criteria, including pediatric patients (≤ 18 y old) who went through surgery (P), received preoperative single-shot ESPB (I), were compared to a control group (without block or sham block) (C). The data encompassed primary results such as intraoperative opioid consumption, total opioid consumption within 24 h postoperatively, and time to first rescue analgesia. Secondary outcomes included postoperative pain scores at 0, 1, 2, 4, 6, 12, and 24 h, the incidence of PONV, as well as side effects or complications related to ESPB and local anesthetic use (O), while the exclusively consisted of randomized controlled trials (RCTs) with added qualitative search terms (S).

2.2. Data extraction

Two individuals (MA and LA) independently conducted the review, assessed each study, and performed data

extraction, which encompassed details such as first author, publication year, sample size, type of surgery, ESPB procedure, local anesthesia used (type, concentration, volume), type of postoperative analgesia, intraoperative opioid consumption, total postoperative opioid consumption within 24 h, time to first rescue analgesia, pain assessment tool, pain scores within 24 h post-surgery, occurrences of PONV, and any adverse effects or complications related to the use of local anesthesia and the ESPB procedure. All opioids used in the studies were standardized to equianalgesic morphine doses (1 mg morphine IV = 10 μg fentanyl/remifentanil IV = 1 μg sufentanil IV). In cases where data were incomplete, written requests were emailed to the respective authors.

2.3. Quality assessment & certainty of the evidence

Two study analysts (EH and AU) evaluated the quality and assessed the bias risk using the Revised Cochrane risk-of-bias tool for randomized trials (RoB 2.0).¹⁵ Any

Table 2: Certainty of evidence using the GRADE approach

Certainty assessment						Effect		Certainty
Outcomes	No of participants (studies)	Risk of bias	Inconsistency	Indirectness	Imprecision	Relative (95% CI)	Absolute (95% CI)	
Intraoperative opioid consumption (morphine equianalgesic in mg/kg)	280 (5 RCTs)	Serious ^a	Serious ^b	Not serious	Serious ^c	-	MD -0.54 (-0.97, -0.11)	⊕○○○ Very low
Postoperative opioid consumption in 24 h (morphine equianalgesic in mg/kg)	180 (4 RCTs)	Not serious	Serious ^b	Not serious	Serious ^c	-	MD -0.12 (-0.21, -0.02)	⊕⊕○○ Low
Time to first rescue analgesia (h)	280 (5 RCTs)	Serious ^a	Serious ^b	Not serious	Serious ^c	-	MD 3.38 (2.38 4.39)	⊕○○○ Very low
Postoperative pain score at 0 h	320 (6 RCTs)	Serious ^a	Serious ^b	Not serious	Serious ^c	-	SMD -0.71 (-1.03, -0.40)	⊕○○○ Very low
Postoperative pain score at 1 h	280 (5 RCTs)	Serious ^a	Serious ^b	Not serious	Serious ^c	-	SMD -1.05 (-2.03, -0.08)	⊕○○○ Very low
Postoperative pain score at 2 h	260 (5 RCTs)	Serious ^a	Serious ^b	Not serious	Serious ^c	-	SMD -0.7 (-1.52, 0.11)	⊕○○○ Very low
Postoperative pain score at 4 h	220 (4 RCTs)	Serious ^a	Serious ^b	Not serious	Serious ^c	-	SMD -1.17 (-2.18, -0.17)	⊕○○○ Very low
Postoperative pain score at 6 h	320 (6 RCTs)	Serious ^a	Serious ^b	Not serious	Serious ^c	-	SMD -0.88 (-1.59, -0.18)	⊕○○○ Very low
Postoperative pain score at 12 h	320 (6 RCTs)	Serious ^a	Serious ^b	Not serious	Serious ^c	-	SMD -0.35 (-1.00, 0.30)	⊕○○○ Very low
Postoperative pain score at 24 h	240 (5 RCTs)	Not serious	Serious ^b	Not serious	Serious ^c	-	SMD -0.38 (-0.98, 0.21)	⊕⊕○○ Low
PONV events	280 (5 RCTs)	Serious ^a	Not serious	Not serious	Serious ^c	OR 0.52 (0.28 to 0.98)	93 fewer per 1,000 (148 fewer to 3 fewer)	⊕⊕○○ Low

Abbreviations: CI, confidence interval; ESPB, erector spinae plane block; GRADE, the Grading of Recommendations Assessment, Development, and Evaluation; MD, mean difference; OR, odds ratio; SMD, standard mean difference.

^aDowngrade the quality of evidence by one level because one study has a risk of biasing intervention and outcome assessment.

^bDowngrade the quality of evidence one level because of heterogeneity $I^2 > 30\%$.

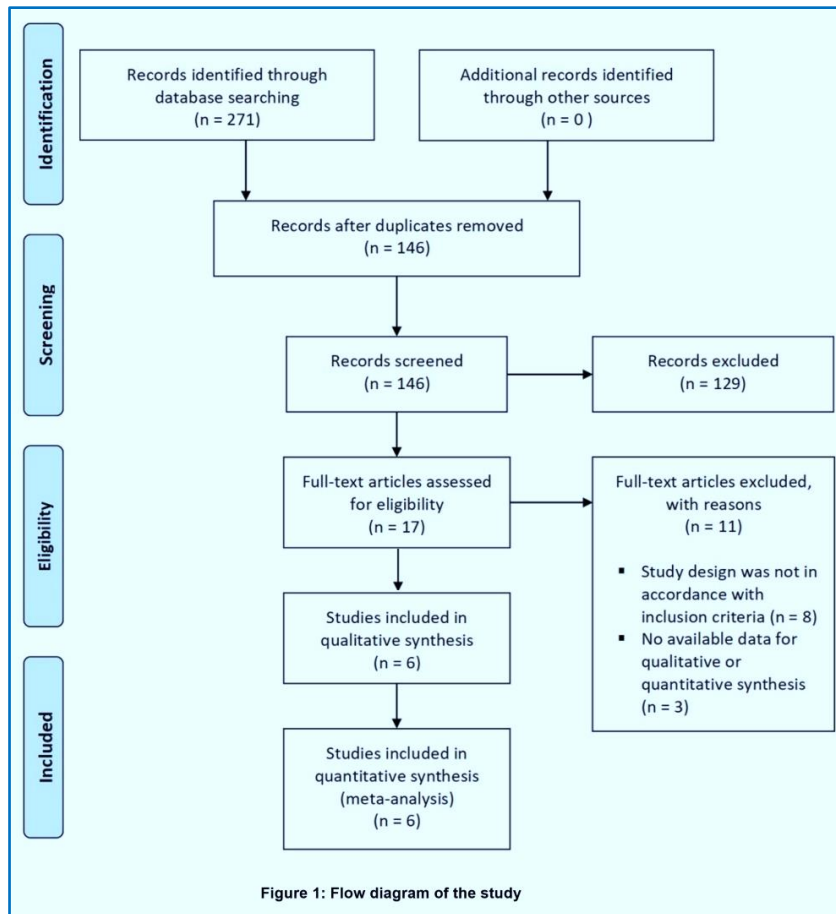
^cDowngrade the quality of evidence by one level because the number of samples does not meet the optimal information size.

disagreements in quality assessment and bias risk were deliberated upon with a third party. The final evaluation was categorized into 1) low risk of bias, 2) some concerns/moderate risk of bias, and 3) high risk of bias, 4) adhering to the descriptions in the Cochrane guidelines. The certainty of the evidence was summarized through the Grading of Recommendations Assessment, Development, and Evaluation (GRADE) methodology for individual outcomes.¹⁶ The GRADEpro GDT software (GRADEpro Guideline Development Tool, McMaster University, 2020) was employed to

facilitate the creation of evidence summaries and recommendations.

2.4. Data synthesis & statistical analysis

Continuous outcomes were documented as mean values and standard deviations (SD). Results presented as median and interquartile range were converted into mean and SD using the formula outlined by Luo et al.,¹⁷ and Wan et al.¹⁸ For data analysis, the Revman 5.4.1 software (The Nordic Cochrane Centre, Denmark) was utilized. In



a situation where continuous data exhibited varying measurement outcomes, standardized mean differences (SMD) with 95% confidence intervals (CIs) were employed. Meanwhile, outcomes with consistent measurements were displayed as mean differences (MD) with 95% CIs. Dichotomous data were analyzed utilizing the Mantel-Haenszel odds ratio, and heterogeneity was assessed using the I^2 statistic. Forest plots reflecting low heterogeneity ($I^2 \leq 30\%$) were presented under fixed effects, while instances of high heterogeneity ($I^2 > 30\%$) were depicted under random effects. When the process was feasible, sub-group analyses were conducted for data showing high heterogeneity.

3. RESULTS

3.1. Study selection and characteristics

A summary of the literature screening process and results following PRISMA guidelines is shown in Figure 1. Six studies^{10–13,19,20} compared the effectiveness of single-shot ESPB analgesia to the control group in pediatric surgeries, encompassing 320 included samples. Table 1 shows the main characteristics of these six studies.

3.2. Quality assessment & certainty of the evidence

The assessment of bias risk using RoB 2.0 indicated that one study had a high risk of bias, while another five^{10,12,13,19,20} were found to have a low risk of bias, as shown in Figure 2. Evaluating evidence quality using the GRADE guidelines produced very low to low-quality ratings, as seen in Table 2.

3.3. Primary outcome

3.3.1. Intraoperative opioid consumption

Five studies^{10–13,19} with a combined sample size of 280, reported total intraoperative opioid consumption. The ESPB group exhibited lower intraoperative opioid consumption compared to the control group (MD: -0.54; 95% CI [-0.97, -0.11], $I^2 = 97\%$, $P = 0.01$, very low-quality certainty of evidence) (Figure 3a).

3.3.2. Total postoperative opioid consumption in 24 h

Four studies^{10,12,13,20} reported total postoperative opioid consumption within 24 h. The postoperative opioid requirement was lower in the ESPB group (MD: -0.12; 95% CI [-0.21, -0.02], $I^2 = 93\%$, $P = 0.02$, low-quality certainty of evidence) (Figure 3b).

3.3.3. Time to first rescue analgesia

In the case of the five studies^{10–12,19,20} with a total sample size of 280, the group receiving single-shot ESPB demonstrated an extended duration to the first rescue analgesia requirement (MD: 3.38; 95% CI [2.38, 4.39], $I^2 = 96\%$, $P < 0.00001$, very low-quality certainty of evidence) (Figure 3c).

3.4. Secondary outcome

3.4.1. Postoperative pain score within 24 h

Five studies^{10,12,13,19,20} assessed pain scores up to 24 h postoperatively, while one study¹¹ evaluated pain up to only 12 h post-surgery. Pain assessment at 0, 6, and 12 h was conducted across all of the six studies. Pain scores at 1, 2, and 24 h were each evaluated by five different studies. Additionally, four studies^{10,11,13,19} assessed pain at 4 h postoperatively.

	Bias arising from the randomization process	Bias due to deviations from intended interventions	Bias due to missing outcome data	Bias in measurement of the outcome	Bias in selection of the reported results	Overall bias
Kaushal 2019	+	?	+	?	+	+
Mostafa 2019	+	+	+	+	+	+
Singh 2020	+	+	+	+	+	+
Abduallah 2022	+	+	+	+	+	+
Karacaer 2022	+	+	+	+	+	+
Yuan 2022	+	+	+	+	+	+

Figure 2: Table showing the degrees of bias in the studies

Significantly lower postoperative pain scores in the ESPB group were observed at 0 h (SMD: -0.71, 95% CI [-1.03, -0.40], $I^2 = 39\%$, $P < 0.00001$, very low-quality certainty of evidence), 1 hour (SMD: -1.05; 95% CI [-2.03, -0.08], $I^2 = 93\%$, $P = 0.03$, very low-quality certainty of evidence), 4 h (SMD: -1.17; 95% CI [-2.18, -0.17], $I^2 = 91\%$, $P = 0.02$, very low-quality certainty of evidence), and 6 h (SMD: -0.88; 95% CI [-1.59, -0.18], $I^2 = 88\%$, $P = 0.01$, very low-quality certainty of evidence). No significant differences in pain scores were observed at 2 h (SMD: -0.70; 95% CI [-1.52, 0.11], $I^2 = 90\%$, $P = 0.09$, very low-quality certainty of evidence), 12 h (SMD: -0.35; 95% CI [-1.00, 0.30], $I^2 = 87\%$, $P = 0.30$, low-quality certainty of evidence), and 24 h (SMD: -0.38; 95% CI [-0.98, 0.21], $I^2 = 77\%$, $P = 0.21$, low-quality certainty of evidence). A summary of the results for postoperative pain scores within 24 h could be seen in Figure 4.

3.4.2. PONV events

PONV events were documented in five studies,^{10–13,19} and the analysis of collected data showed that the odds ratio (OR) for PONV was significantly lower in the ESPB group (OR: 0.52; 95% CI [0.28, 0.98], $I^2 = 5\%$, $P = 0.04$, low-quality certainty of evidence) as shown in Figure 5.

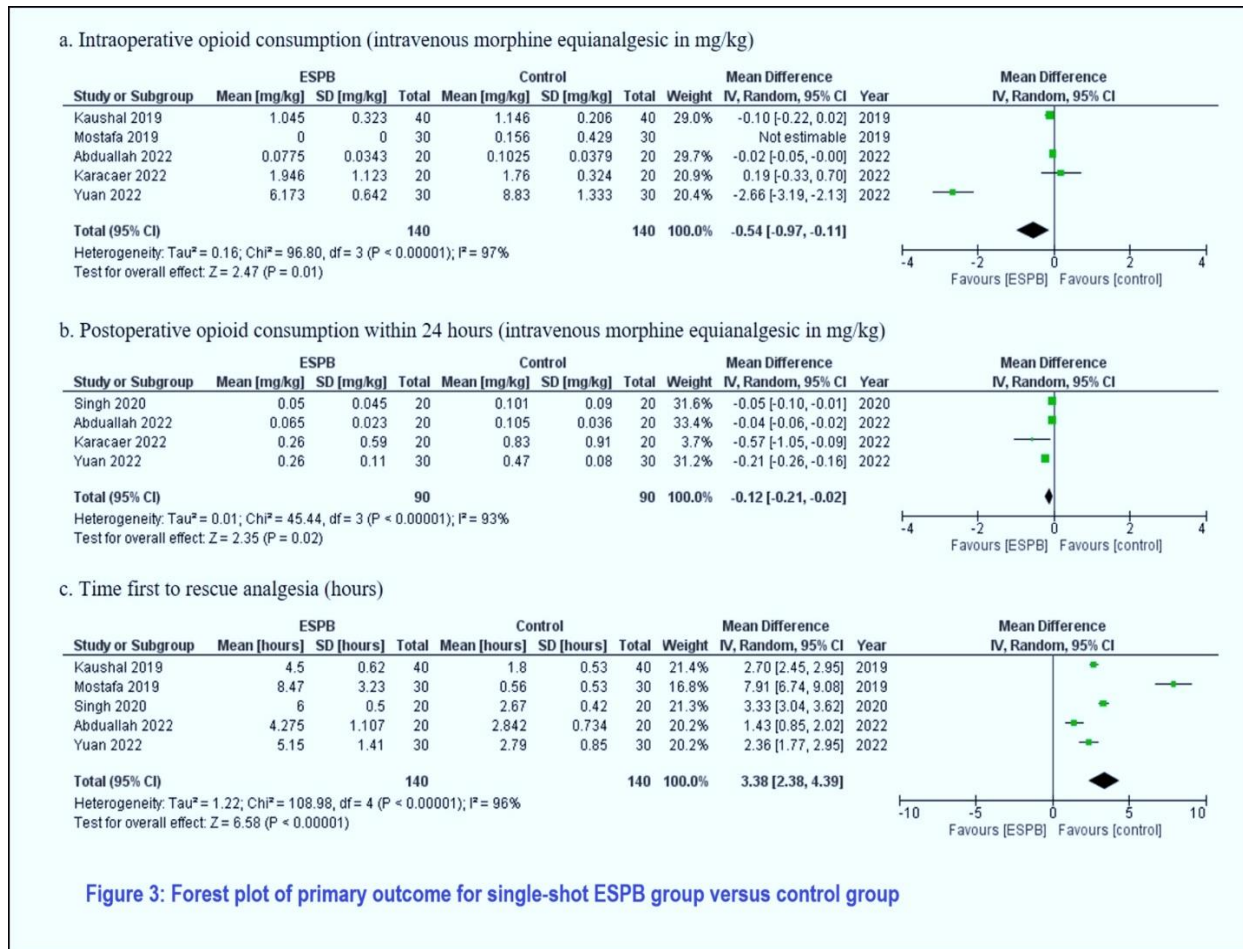
3.4.3. Complications related to local anesthesia & ESPB procedure

All studies in the current analysis reported no complications associated with using local anesthesia or the ESPB procedure guided by ultrasound.

4. DISCUSSION

This meta-analysis revealed that preoperative single-shot ESPB in pediatrics reduced both intra and postoperative opioid requirements, prolonged the time first to rescue analgesia, and alleviated pain for up to 6 h post-surgery, with very low to low certainty of evidence quality. The ESPB, a recently introduced fascial plane block, entailed the administration of local anesthesia within the fascial plane between the erector spinae muscle and the transverse processes of the vertebrae.^{21,22} The precise mechanism underlying the analgesic effect of ESPB remained uncertain. Adult cadaver studies examining dye dispersion yielded varying results. For example, Ivanusic et al.²³ observed dye dispersion into the posterior dorsal ramus of the costotransverse ligament; while Adhikary et al.²⁴ and Yang et al.²⁵ noted dye spread to the anterior side of the transverse process, encompassing the paravertebral space, neural foramina, ipsilateral epidural space, and ipsilateral sympathetic branches. Studies conducted in the pediatric age range had predominantly focused on neonates. Those on two neonatal cadavers demonstrated dye spread into the anterior paravertebral and epidural spaces, intercostal spaces, and dorsal and ventral spinal nerve roots.²⁶ Neonates and infants possessed more flexible spines, less dense ligaments, and cartilaginous laminae, potentially enabling a broader distribution of local anesthetic volume.

The present meta-analysis aligned with studies conducted in adult populations, illustrating the effects of single-shot ESPB in reducing perioperative opioid consumption.²² Opioids have historically played a crucial role in perioperative pain management in pediatrics. However, its usage often led to various side effects, including nausea and vomiting, pruritus, constipation, sedation, and potentially fatal respiratory depression in pediatric patients. Adopting multimodal analgesia, including regional and non-opioid, was preferred for opioid-sparing or opioid-free anesthesia concepts. The region offered optimal perioperative analgesia and mitigated stress responses in infants and children. When not contraindicated, regional anesthesia should ideally be employed for postoperative pain management in all pediatric surgical cases to reduce opioid requirements.² The results of the current meta-analysis suggested that single-shot ESPB served as an opioid-sparing analgesic option for surgeries with severe pain intensity. Furthermore, Thomas and Tulgar²⁷

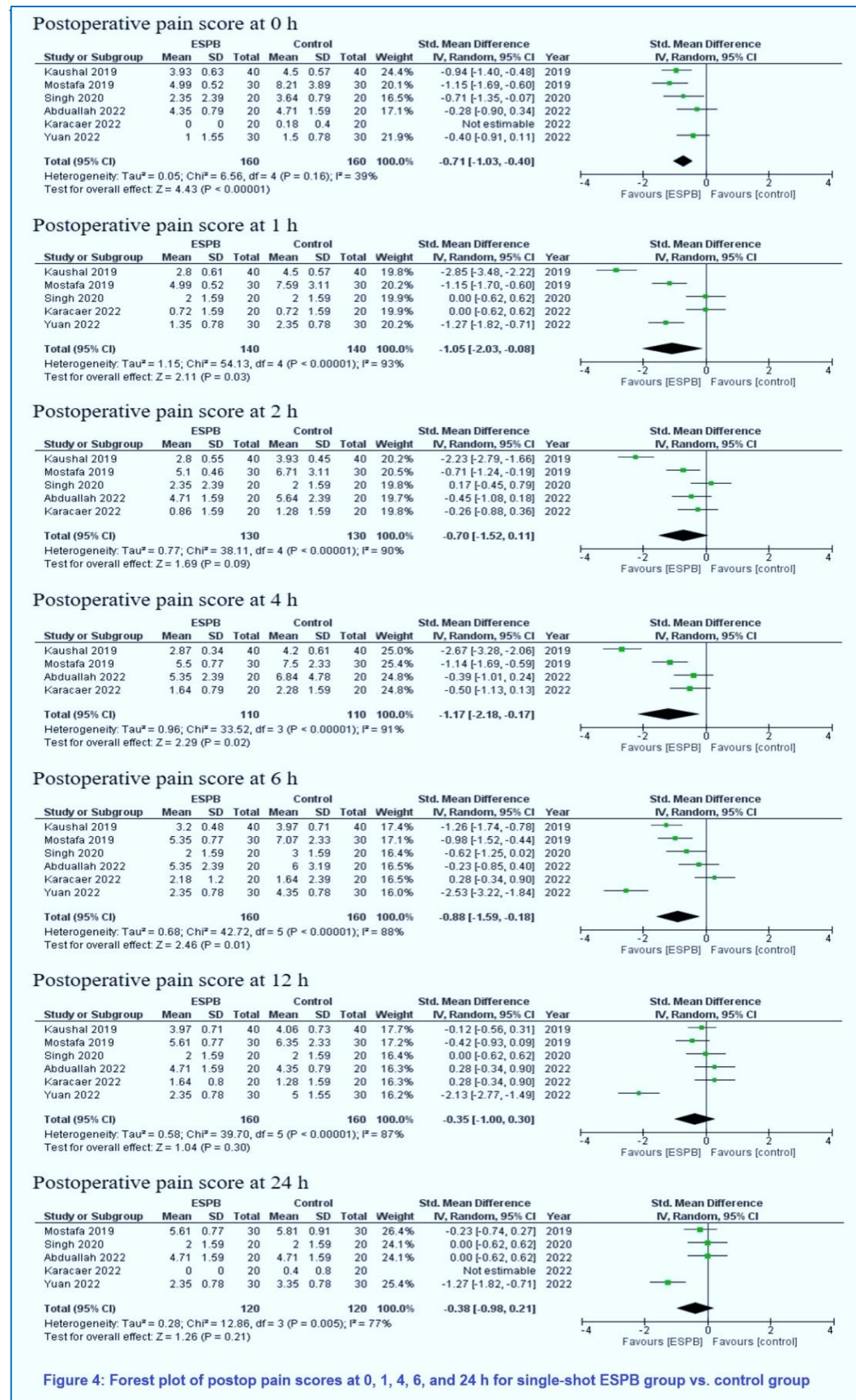


reported that bilateral ESPB combined with opioid-free anesthesia provided effective pain control after laparoscopic cholecystectomy. Based on another case study, ESPB minimized exposure to general anesthesia in premature infants undergoing inguinal hernia surgery,²⁸ implying ESPB could be utilized as a sole anesthetic for specific surgeries. Another advantage of opioid-sparing analgesia was the reduced incidence of PONV. In this analysis, PONV was lower in the ESPB group. Although not life-threatening, PONV causes discomfort for the patient and can exacerbate parental dissatisfaction. Additionally, PONV can lead to increased length of stay in the PACU and possible complications of dehydration and pulmonary aspiration.²⁹

The discovery of reduced pain scores in the ESPB group up to six hours post-surgery in the present meta-analysis aligned with a prior study on adult populations undergoing diverse surgical procedures.³⁰ However, several meta-analyses on adults undergoing spinal surgery demonstrated that the pain-reducing effects of ESPB extended to the 24 to 48 h post-surgery.^{31,32} Multiple factors, such as the type and duration of surgery

and the type and dose of local anesthetic used, can affect the results of postoperative pain assessment. In contrast to other studies within this meta-analysis, Yuan et al.,¹² stated that ESPB alleviated pain for up to 24 h post-surgery. This outcome could be attributed to the employment of minimally invasive video-assisted thoracoscopic surgery (VATS), which minimized surgical trauma and subsequently reduced postoperative pain.

In the context of the same surgical procedure, Kaushal et al.,¹¹ demonstrated the pain-reduction effects of ESPB extending up to ten hours post-surgery, while Karacaer et al.,¹³ did not identify a significant disparity in pain scores up to 24 h post-surgery between the ESPB group and the control group. Variations in the surgery duration and the total dose of administered local anesthesia in these two studies potentially influenced the outcomes of postoperative pain scores. The characteristics of nerve blocks hinged on the distribution of local anesthesia in proximity to the targeted nerves.³³ In fascial plane blocks, achieving optimal dermatomal coverage necessitated a larger volume of local anesthesia. Moreover, local anesthetics with heightened protein



escalating the potential for extending the block duration through increased dosages. A study focusing on pediatric transversus abdominal plane (TAP) blocks, employing two distinct doses of local anesthesia, showed that a higher dose contributed to prolonged analgesia duration and diminished requirements for supplementary analgesia within 24 h.³⁴

The proficiency of the anesthesiologist in conducting ESPB procedures could also give rise to varying analgesic effects.³⁵ This became apparent through several studies, involving adult cadaver ESPB, which exhibited diverse patterns of dye dispersion. Furthermore, discrepancies in interventions encompassing postoperative supplementary analgesia could impact postoperative pain scores. Another pivotal factor pertained to the variance in pain assessment tools, which had no universal application across all age groups to date, so the available tools must be adapted to each age group.³ Moreover, sociocultural elements could influence pain perception, as evidenced in a study on pain assessment. A study utilized the FLACC scale and produced superior outcomes compared to the CHEOPS, OPS, and TPPS (Toddler Preschool Postoperative Pain Scale) scales for Pakistani children aged 3-7 years.³⁶

The six studies included in this meta-analysis did not report any complications related to local anesthesia. The ESPB represented a volume-based fascial plane block, which entailed a potential systemic local anesthesia toxicity risk. The maximum dose limit for each block varied due to the tissue vascularization within the blocked area, influencing the systemic absorption of local anesthesia. In the case of ESPB, employing 150 mg of ropivacaine led to a plasma concentration of 1.4 ± 0.3 $\mu\text{g/mL}$ after thirty minutes.³⁷ This plasma concentration remained well below the threshold value for ropivacaine plasma toxicity, which stood at 4.3 $\mu\text{g/mL}$. De Cassai et al.,³⁸ affirmed that the plasma concentration of lidocaine at 3.5 mg/kg of ideal body weight in ESPB did not reach the threshold for lidocaine toxicity (5 $\mu\text{g/mL}$). However, no available publication existed containing plasma concentration data for bupivacaine and levobupivacaine after ESPB injection.

Ultrasound guidance is very convenient, so a single-shot ESPB only takes 10 min,⁹ and 18 min when accompanied by catheter placement.³⁹ The injection site for ESPB maintained a considerable distance from the spinal cord, causing a shallow risk of spinal cord damage. Ultrasound guidance assisted in visualizing the injection site, needle trajectory, and local anesthetic deposition, which helped prevent and mitigate complications. It should be noted that none of the six studies encompassed within this meta-analysis documented any complications associated with ESPB. These results indicated that implementing

ultrasound-guided ESPB in pediatrics was a safe approach.

5. LIMITATIONS

The number of studies and the sample sizes involved were small. Secondly, there existed a notable degree of heterogeneity within the overall analysis; however, conducting subgroup analyses could have been more feasible due to the limited number of studies available. Factors contributing to this high heterogeneity encompassed the diversity in surgical procedures, variations in the employment of local anesthesia, differences in pain assessment tools, and discrepancies in interventions. The study furnished evidence of very low to low quality. Contributing factors to the low-quality evidence included a high risk of bias within the encompassed studies, inconsistencies in outcomes stemming from considerable heterogeneity, and limited sample size information.

6. CONCLUSION

In conclusion, preoperative single-shot erector spinae plane block proved effective for providing perioperative analgesia in pediatric patients. Implementing ultrasound-guided erector spinae plane block ensured protection against systemic local anesthesia toxicity and associated complications, making it a promising approach for opioid-sparing analgesia. Consequently, there is a need for additional studies encompassing larger sample sizes and randomized controlled trials to facilitate a more comprehensive investigation.

7. Data availability

The numerical data generated during this research is available with the authors.

8. Acknowledgement

We gratefully thank Faculty of Medicine

9. Conflict of interest

The study utilized the hospital resources only, and no external or industry funding was involved.

10. Authors' contribution

MA, AU: Concept, conduction of the study work and manuscript editing

RS, LA: Conduction of the study work

EH: Conduction of the study work and manuscript editing

11. REFERENCES

1. Makhlof MM, Garibay ER, Jenkins BN, Kain ZN, Fortier MA. Postoperative pain: factors and tools to improve pain management in children. *Pain Manag.* 2019;9(4):389-397. PMID: 31215311 DOI: 10.2217/pmt-2018-0079

2. Lönnqvist P-A, Morton NS. Postoperative analgesia in infants and children. *Br J Anaesth.* 2005;95(1):59-68. PMID: [15668207](#) DOI: [10.1093/bja/aei065](#)
3. Cettler M, Zielińska M, Rosada-Kurasińska J, Kubica-Cielińska A, Jarosz K, Bartkowska-Śniatkowska A. Guidelines for treatment of acute pain in children - the consensus statement of the Section of Paediatric Anaesthesiology and Intensive Therapy of the Polish Society of Anaesthesiology and Intensive Therapy. *Anaesthesiol Intensive Ther.* 2022;54(3):197-218. PMID: [36189904](#) DOI: [10.5114/ait.2022.118972](#)
4. Alexander JC, Patel B, Joshi GP. Perioperative use of opioids: Current controversies and concerns. *Best Pract Res Clin Anaesthesiol.* 2019;33(3):341-351. PMID: [31785719](#) DOI: [10.1016/j.bpa.2019.07.009](#)
5. Roberts K, Brindle M, McLuckie D. Enhanced recovery after surgery in paediatrics: a review of the literature. *BJA Educ.* 2020;20(7):235-241. PMID: [33456956](#) DOI: [10.1016/j.bjae.2020.03.004](#)
6. Krodel D, Marcelino R, Sawardekar A, Suresh S. Pediatric Regional Anesthesia: A Review and Update. *Curr Anesthesiol Rep.* 2017;7. DOI: [10.1007/s40140-017-0214-9](#)
7. Forero M, Adhikary SD, Lopez H, Tsui C, Chin KJ. The Erector Spinae Plane Block: A Novel Analgesic Technique in Thoracic Neuropathic Pain. *Reg Anesth Pain Med.* 2016;41(5):621-627. PMID: [27501016](#) DOI: [10.1097/AAP.0000000000000451](#)
8. Muñoz F, Cubillos J, Bonilla AJ, Chin KJ. Erector spinae plane block for postoperative analgesia in pediatric oncological thoracic surgery. *Can J Anesth.* 2017;64(8):880-882. PMID: [28447318](#) DOI: [10.1007/s12630-017-0894-0](#)
9. Holland EL, Bosenberg AT. Early experience with erector spinae plane blocks in children. *Paediatr Anaesth.* 2020;30(2):96-107. PMID: [31883421](#) DOI: [10.1111/pan.13804](#)
10. Abdulllah MA, Al-Ahwal LA, Ahmed SA. Effect of erector spinae plane block on postoperative analgesia after pediatric hip surgery: Randomized controlled study. *Pain Pract.* 2022;22(4):440-446. PMID: [35032350](#) DOI: [10.1111/papr.13099](#)
11. Kaushal B, Chauhan S, Magoon R, Krishna NS, Saini K, Bhoi D, et al. Efficacy of Bilateral Erector Spinae Plane Block in Management of Acute Postoperative Surgical Pain After Pediatric Cardiac Surgeries Through a Midline Sternotomy. *J Cardiothorac Vasc Anesth.* 2020;34(4):981-986. PMID: [31515190](#) DOI: [10.1053/j.jvca.2019.08.009](#)
12. Yuan Z, Liu J, Jiao K, Fan Y, Zhang Y. Ultrasound-guided erector spinae plane block improve opioid-sparing perioperative analgesia in pediatric patients undergoing thoracoscopic lung lesion resection: a prospective randomized controlled trial. *Transl Pediatr.* 2022;11(5):706-714. PMID: [35685082](#) DOI: [10.21037/tp-22-118](#)
13. Karacaer F, Biricik E, Ilginel M, Tunay D, Topçuoğlu Ş, Ünlügenc H. Bilateral erector spinae plane blocks in children undergoing cardiac surgery: A randomized, controlled study. *J Clin Anesth.* 2022;80:110797. PMID: [35489304](#) DOI: [10.1016/j.jclinane.2022.110797](#)
14. Moher D, Shamseer L, Clarke M, Ghersi D, Liberati A, Petticrew M, et al. Preferred reporting items for systematic review and meta-analysis protocols (PRISMA-P) 2015 statement. *Syst Rev.* 2015;4(1):1. PMID: [25554246](#) DOI: [10.1186/2046-4053-4-1](#)
15. Sterne JAC, Savović J, Page MJ, Elbers RG, Blencowe NS, Boutron I, et al. RoB 2: a revised tool for assessing risk of bias in randomised trials. *BMJ.* 2019;366:l4898. PMID: [31462531](#) DOI: [10.1136/bmj.l4898](#)
16. Granholm A, Alhazzani W, Møller MH. Use of the GRADE approach in systematic reviews and guidelines. *Br J Anaesth.* 2019;123(5):554-559. PMID: [31558313](#) DOI: [10.1016/j.bja.2019.08.015](#)
17. Luo D, Wan X, Liu J, Tong T. Optimally estimating the sample mean from the sample size, median, mid-range, and/or mid-quartile range. *Stat Methods Med Res.* 2018;27(6):1785-1805. PMID: [27683581](#) DOI: [10.1177/0962280216669183](#)
18. Wan X, Wang W, Liu J, Tong T. Estimating the sample mean and standard deviation from the sample size, median, range and/or interquartile range. *BMC Med Res Methodol.* 2014;14(1):135. PMID: [25524443](#) DOI: [10.1186/1471-2288-14-135](#)
19. Mostafa SF, Abdelghany MS, Abdelraheem TM, Abu Elyazed MM. Ultrasound-guided erector spinae plane block for postoperative analgesia in pediatric patients undergoing splenectomy: A prospective randomized controlled trial. *Paediatr Anaesth.* 2019;29(12):1201-1207. PMID: [31630465](#) DOI: [10.1111/pan.13758](#)
20. Singh S, Jha RK, Sharma M. The analgesic effect of bilateral ultrasound-guided erector spinae plane block in paediatric lower abdominal surgeries: A randomised, prospective trial. *Indian J Anaesth.* 2020;64(9):762-767. PMID: [33162570](#) DOI: [10.4103/ija.IJA_630_20](#)
21. Kot P, Rodriguez P, Granell M, Cano B, Rovira L, Morales J, et al. The erector spinae plane block: a narrative review. *Korean J Anesthesiol.* 2019 Jun;72(3):209-220. PMID: [30886130](#) DOI: [10.4097/kja.d.19.00012](#)
22. Cui Y, Wang Y, Yang J, Ran L, Zhang Q, Huang Q, et al. The Effect of Single-Shot Erector Spinae Plane Block (ESPB) on Opioid Consumption for Various Surgeries: A Meta-Analysis of Randomized Controlled Trials. *J Pain Res.* 2022;15:683-699. PMID: [35281481](#) DOI: [10.2147/JPR.S346809](#)
23. Ivanusic J, Konishi Y, Barrington MJ. A Cadaveric Study Investigating the Mechanism of Action of Erector Spinae Blockade. *Reg Anesth Pain Med.* 2018;43(6):567-571. PMID: [29746445](#) DOI: [10.1097/AAP.0000000000000789](#)
24. Adhikary S Das, Bernard S, Lopez H, Chin KJ. Erector Spinae Plane Block Versus Retrolaminar Block: A Magnetic Resonance Imaging and Anatomical Study. *Reg Anesth Pain Med.* 2018;43(7):756-762. PMID: [29794943](#) DOI: [10.1097/AAP.0000000000000798](#)
25. Yang HM, Choi YJ, Kwon HJ, O J, Cho TH, Kim SH. Comparison of injectate spread and nerve involvement between retrolaminar and erector spinae plane blocks in the thoracic region: a cadaveric study. *Anaesthesia.* 2018;73(10):1244-1250. PMID: [30113699](#) DOI: [10.1111/anae.14408](#)
26. Govender S, Mohr D, Bosenberg A, Van Schoor AN. A cadaveric study of the erector spinae plane block in a neonatal sample. *Reg Anesth Pain Med.* 2020;45(5):386-388. PMID: [32047107](#) DOI: [10.1136/rapm-2019-100985](#)
27. Thomas DT, Tulgar S. Ultrasound-guided Erector Spinae Plane

- Block in a Child Undergoing Laparoscopic Cholecystectomy. *Cureus*. 2018;10(2):e2241. PMID: [29719743](#) DOI: [10.7759/cureus.2241](#)
28. Hernandez MA, Palazzi L, Lapalma J, Cravero J. Erector spinae plane block for inguinal hernia repair in preterm infants. *Paediatr Anaesth*. 2018;28(3):298-299. PMID: [29341379](#) DOI: [10.1111/pan.13325](#)
 29. Ames WA, Machovec K. An update on the management of PONV in a pediatric patient. *Best Pract Res Clin Anaesthesiol*. 2020;34(4):749-758. PMID: [33288124](#) DOI: [10.1016/j.bpa.2020.05.007](#)
 30. Kendall MC, Alves L, Traill LL, De Oliveira GS. The effect of ultrasound-guided erector spinae plane block on postsurgical pain: a meta-analysis of randomized controlled trials. *BMC Anesthesiol*. 2020;20(1):99. PMID: [32357842](#) DOI: [10.1186/s12871-020-01016-8](#)
 31. Ma J, Bi Y, Zhang Y, Zhu Y, Wu Y, Ye Y, et al. Erector spinae plane block for postoperative analgesia in spine surgery: a systematic review and meta-analysis. *Eur spine J Off Publ Eur Spine Soc Eur Spinal Deform Soc Eur Sect Cerv Spine Res Soc*. 2021;30(11):3137-3149. PMID: [33983515](#) DOI: [10.1007/s00586-021-06853-w](#)
 32. Fu MY, Hao J, Ye LH, Jiang W, Lv YW, Shen JL, et al. Efficacy and Safety of Erector Spinae Plane Block for Perioperative Pain Management in Lumbar Spinal Surgery: A Systematic Review and Meta-Analysis of Randomized Controlled Trials. *J Pain Res*. 2023;16:1453-1475. PMID: [37163199](#) DOI: [10.2147/JPR.S402931](#)
 33. Madsen MH, Christiansen CB, Rothe C, Lundstrøm LH, Lange KHW. Longitudinal neural exposure to local anesthetic and nerve block duration: a retrospective analysis of experimental data from healthy volunteer trials. *Reg Anesth Pain Med*. 2020;45(3):192-197. PMID: [31932487](#) DOI: [10.1136/rapm-2019-100988](#)
 34. Suresh S, Birmingham PK, Kozlowski RJ. Pediatric pain management. *Anesthesiol Clin*. 2012;30(1):101-117. PMID: [22405436](#) DOI: [10.1016/j.anclin.2011.12.003](#)
 35. Cai Q, Liu GQ, Huang LS, Yang ZX, Gao ML, Jing R, et al. Effects of erector spinae plane block on postoperative pain and side-effects in adult patients underwent surgery: A systematic review and meta-analysis of randomized controlled trials. *Int J Surg*. 2020;80:107-116. PMID: [32461196](#) DOI: [10.1016/j.ijsu.2020.05.038](#)
 36. Shamim F, Ullah H, Khan FA. Postoperative pain assessment using four behavioral scales in Pakistani children undergoing elective surgery. *Saudi J Anaesth*. 2015;9(2):174-178. PMID: [25829906](#) DOI: [10.4103/1658-354X.152874](#)
 37. Kang R, Lee S, Kim GS, Jeong JS, Gwak MS, Kim JM, et al. Comparison of Analgesic Efficacy of Erector Spinae Plane Block and Posterior Quadratus Lumborum Block in Laparoscopic Liver Resection: A Randomized Controlled Trial. *J Pain Res*. 2021;14:3791-3800. PMID: [34924770](#) DOI: [10.2147/JPR.S343366](#)
 38. De Cassai A, Bonanno C, Padrini R, Geraldini F, Boscolo A, Navalesi P, et al. Pharmacokinetics of lidocaine after bilateral ESP block. *Reg Anesth Pain Med*. 2021;46(1):86-89. PMID: [32868484](#) DOI: [10.1136/rapm-2020-101718](#)
 39. Gomez G, Osterbauer B, Nguyen R, Wee CP, Kochhar A, Tai T, et al. Microtia Reconstruction and Erector Spinae Block in Children: A Case Series With Chart Review. *Otolaryngol Head Neck Surg*. 2022;166(2):382-387. PMID: [34126812](#) DOI: [10.1177/01945998211018382](#)