

ORIGINAL RESEARCH

REGIONAL ANESTHESIA

Ultrasound-guided three-in-one block versus landmark-based fascia iliaca compartment block for analgesia prior to positioning for spinal anesthesia in femur fracture patients

Rhendra Hardy Mohamad Zaini¹, Ikwan Wan Mohd Rubi², Wan Mohd Nazaruddin Wan Hassan³, Umairah Esa⁴, Muhamad Aizuddin Ismail⁵, Praveena Seevaunnamtum⁶, Sanihah Che Omar⁷

Author affiliations:

1. Rhendra Hardy Mohamad Zaini¹, MD, MMed, Associate Professor, Department of Anesthesiology & Intensive Care, School of Medical Sciences & Hospital, Health Campus, Universiti Sains Malaysia, 16150 Kubang Kerian, Kelantan, Malaysia; E-mail: rhendra@gmail.com
2. Ikwan Wan Mohd Rubi², MD, MMed, Anesthesiologist, Department of Anesthesiology & Intensive Care, School of Medical Sciences & Hospital, Health Campus, Universiti Sains Malaysia, 16150 Kubang Kerian, Kelantan, Malaysia; E-mail: ikhwanwmr@gmail.com
3. Wan Mohd Nazaruddin Wan Hassan³, MD, MMed, Associate Professor, Department of Anesthesiology & Intensive Care, School of Medical Sciences & Hospital, Health Campus, Universiti Sains Malaysia, 16150 Kubang Kerian, Kelantan, Malaysia; E-mail: nazarudin@usm.my
4. Umairah Esa⁴, MD, MMed, Lecturer, Department of Anesthesiology & Intensive Care, School of Medical Sciences & Hospital, Health Campus, Universiti Sains Malaysia, 16150 Kubang Kerian, Kelantan, Malaysia; E-mail: umairahesa@usm.my
5. Muhamad Aizuddin Ismail⁵, MD, MMed, Lecturer, Department of Anesthesiology & Intensive Care, School of Medical Sciences & Hospital, Health Campus, Universiti Sains Malaysia, 16150 Kubang Kerian, Kelantan, Malaysia; E-mail: maism157@gmail.com
6. Praveena Seevaunnamtum, MD, MMed, Senior Lecturer, Department of Anesthesiology & Intensive Care, School of Medical Sciences & Hospital, Health Campus, Universiti Sains Malaysia, 16150 Kubang Kerian, Kelantan, Malaysia; E-mail: praveenaseeva@usm.my
7. Sanihah Che Omar, MD, MMed, Senior Lecturer, Department of Anesthesiology & Intensive Care, School of Medical Sciences & Hospital, Health Campus, Universiti Sains Malaysia, 16150 Kubang Kerian, Kelantan, Malaysia; E-mail: sanilah_che@usm.my

*Correspondence: Sanihah Che Omar, Tel: +60122159484; Fax: +6097653370; E-mail: sanilah_che@usm.my

ABSTRACT

Background & objective: Femoral bone fracture may cause considerable amount of pain. Many techniques have been described to ease pain in this group of patients. However, regional block technique remains underutilised and not regularly done. We evaluated the efficacy of ultrasound-guided (USG) 3-in-1 femoral nerve block versus the landmark-based single shot fascia iliaca compartment block as an analgesia method prior to positioning for spinal anesthesia in patients going for femur fracture surgery.

Methodology: A total of 60 patients aged between 18 to 65 years old from ASA class I to III were included. They were divided into two groups by using computer assisted randomization. Group I received single shot landmark based-fascia iliaca compartment block whereas Group II received USG femoral 3-in-1 block. Ropivacaine 0.375% was used in both groups with a total volume depends on patient body weight. The pain score at rest, upon movement and at interval of 5-10 min after block performed recorded using Visual Analog Score.

Results: Ultrasound guided femoral 3-in-1 block provides faster pain reduction at least 5-min post block (1.7 ± 0.75 , $P = 0.011$) and significant relief at 20-min post block (1.33 ± 1.16 , $P = 0.026$). Less intravenous fentanyl was required for rescue analgesia in Group II (10.83 ± 29.13 , $P = 0.018$).

Conclusion: Femoral 3-in-1 block provides much faster relief of pain in femoral bone fracture but both blocks are equally effective if given enough time to work out. Both are equally effective and appeared to be safe.

Abbreviations: USG- ultrasound-guided; VAS- Visual Analog Scale score

Keywords: Analgesia; Ultrasound guided femoral 3-in-1; Blind fascia iliaca compartment block; Visual Analog Score; Positioning; Femur fracture.

Citation: Zaini RHM, Rubi IWM, Wan Hassan WMN, Umairah Esa, Ismail MA, Seevaunnamtum P, Omar SC. Ultrasound-guided three-in-one block versus landmark-based fascia iliaca compartment block for analgesia prior to positioning for spinal anesthesia in femur fracture patients. *Anaesth. pain intensive care* 2024;28(2):221–226.

DOI: [10.35975/apic.v28i2.2425](https://doi.org/10.35975/apic.v28i2.2425)

Received: January 13, 2024; **Revised:** February 13, 2024; **Accepted:** February 14, 2024

1. INTRODUCTION

Shaft of femur fracture can be significantly painful due to periosteum injury. This is because the periosteum has the lowest pain threshold of the deep somatic structures. Most of patient will experience different degree of pain depending on their pain threshold level. The intensity of pain is most significant upon movement such as being transported from bed to transportation trolley or vice versa and during sitting upright position for regional anesthesia.

The spinal anesthesia (SA) is the most common technique performed for regional anesthesia in femur fracture surgery. Regional anesthesia has become the preferred technique as it carries lower mortality rate compared to general anesthesia.¹ The mortality rate is reduced by one third when patient is allocated under regional anesthesia. Apart from that, regional anesthesia is associated with lower postoperative complication such as deep venous thrombosis, pulmonary embolism, transfusion requirements, pneumonia, respiratory depression, myocardial infarction, and renal failure.²

A good pain management during preoperative period in femur fracture surgery may allow patients to correctly position themselves during preparation for SA and renders it to be more successfully delivered. Correct position allows maximal separation between the lumbar laminae and the spine, also avoiding rotation and lateral curvature of the whole spine.³ Adequate and proper positioning may expedite process of induction, improve patient satisfaction prior induction of regional anesthesia and reduces complication from marked haemodynamic changes due to pain induced sympathetic stimulation. Severe pain intensity may also cause improper position for SA making the process of giving SA be quite difficult.

Spinal anesthesia or combine spinal epidural has been commonly preferred for fixation of femoral bone fracture especially elderly. Study by McLaren et al⁴ showed that there is increased in mortality rate in patients operated under general anesthesia. However, to put patient in proper positioning prior to giving SA may cause considerable amount of pain. In most circumstances, the discomfort is undertreated and

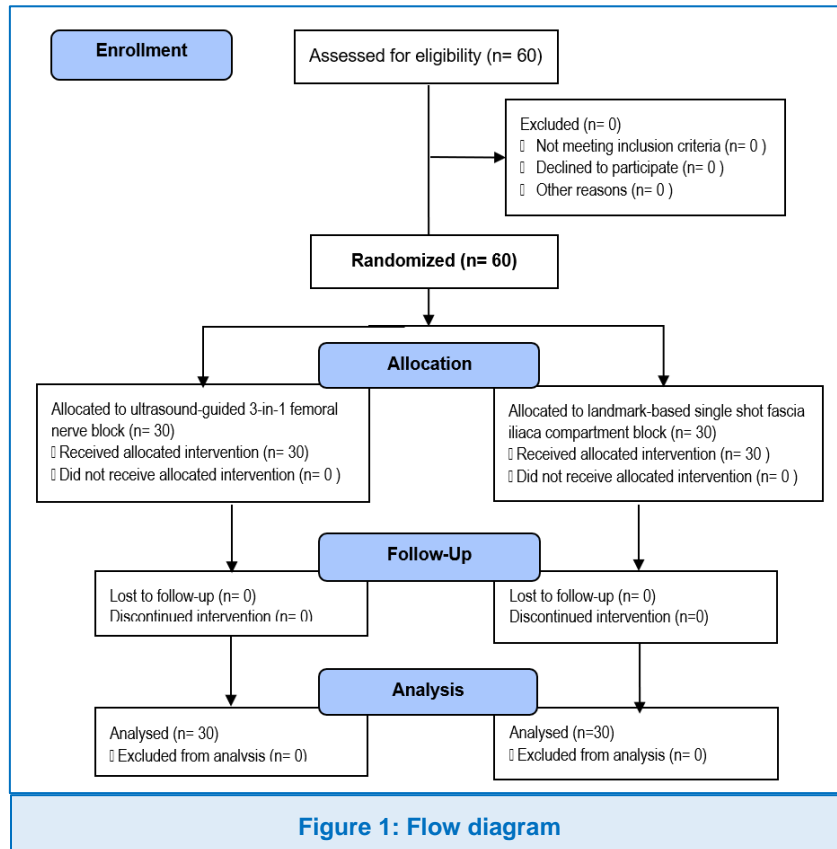
neglected. The most common treatment given is the intravenous opioid and this carries significant risk especially in elderly or opioids naïve patients. Thus, the role of peripheral nerve block has been explored in reducing pain associated with femoral bone fractures.

Many techniques have been described, which was started as anterior approach of inguinal paravascular technique. This technique was also known as 3-in-1 femoral nerve block (FNB).⁵ Fascia iliaca compartment block (FICB) was subsequently discovered to replace 3-in-1 FNB technique for blocking the lateral femoral cutaneous, femoral nerve and obturator nerve.⁶ Both techniques had been described differently nowadays with some of modification or preferences. This study aimed to compare the efficacy of USG 3-in-1 FNB versus the landmark-based single shot FICB.

2. METHODOLOGY

This study was a prospective, randomized controlled trial, which has been approved by the Ethics Committee of University Sains Malaysia (JEPeM Code: USM/JEPeM/15100313). The study was registered at ClinicalTrials.gov (NCT03139617). This clinical research was done following the ethical principles for medical research involving human subjects in accordance with the Helsinki Declaration 2013. The study was conducted after obtaining written consent from the selected patients. A total of 60 American Society of Anesthesiologists (ASA) physical status I-III patients, aged of 18 to 65 years, scheduled for fixation of femur fractures were included in the study. The exclusion criteria include bleeding diathesis, allergic to local anesthetic agent, severe liver disease, malnutrition and hypoalbuminemia.

The patients were randomized into two groups using computer-generated randomization. Group A received single shot fascia iliaca compartment block (FICB) using landmark technique, whereas Group B received USG 3-in-1 femoral nerve block (FNB) (Figure 1). Both block was performed by the principal investigator in the operation theatre. Patient were instructed on the use of visual analog score during recruitment. In the OT, an 18G intravenous (IV) cannula was inserted and standard monitoring including noninvasive blood pressure,



performed without using the nerve stimulator or ultrasound. By using a blunted needle (24G, plexufix needle), identification of puncturing intended space was felt 2 times described as loss of resistance (clicks or plops) indicating the punctured of fascia lata and fascia iliaca. After careful aspiration with syringe to rule out inadvertent intravascular injection, a total volume of local anesthetic (LA) was given per body weight. Bolus of LA given in 2-3 min duration with repeated aspiration. There was no case of accidental vascular puncture during the block procedure.

Patient in Group B received USG femoral 3 in 1 block using insulated stimulating needle (Stimuplex® D Plus 22g x 2", B Braun Melsungen AG 34209 Melsungen Germany). Initial plan to use nerve stimulator was abandoned as contraction of quadriceps femoris might precipitate pain to the patient. Ultrasound was used to locate the

peripheral pulse oximetry, and electrocardiography were put in place. In both groups, block was given to the patient in supine position, under aseptic technique using chlorhexidine solution and draped with sterile medical towel. Both groups received lignocaine 2% for local anesthetic infiltration at the punctured site. Ropivacaine 0.375% was used in both groups with a total volume

depends on patient body weight (30-40 kg = Total dose 3.75 mg/mL x 20 mL= 75 mg, 40-60 kg = Total dose 3.75 mg /mL x 30 mL= 112.5 mg, > 60 kg = Total dose 3.75 mg/mL x 40 mL= 150 mg).

Patient in Group A received fascia iliaca compartment block using blunted needle (Plexufix® 24G x 2", B Braun Melsungen AG 34209 Melsungen Germany). The block was performed as what being described by Dalens et al [6] using anatomical landmark technique. A line was drawn from pubic tubercle to anterior superior iliac spine (ASIS) and divided into 3 equal parts. The punctured point is 2-3cm distal to the point where medial 2/3rd and lateral 1/3rd of the line meet. The femoral vessel was identified lie medial to the punctured site. The fascia iliaca block was

femoral vessel and nerve and by using 'in plane' technique, the skin was punctured with the insulated needle and advance in transverse plane at around 30° angle to the skin. Local anesthetic solution as per ideal

Table 1: Demographic profile

Characteristic	Group A (FICB) n = 30	Group B (Fem 3 in 1) n = 30
Gender *		
• Male	24 (80.0)	23 (76.7)
• Female	6 (20.0)	7 (23.3)
Race *		
• Malay	29(96.7)	29(96.7)
• Others	1(3.3)	1(3.3)
ASA *		
• I	20 (66.7)	22 (73.3)
• II	7(23.3)	8(26.7)
• III	3(10)	0(0)
BMI (kg /m²) †	24.20 ± 3.54	24.67 ± 2.38
Age (y) †	36.87 ± 18.02	36.87 ± 17.85
<i>Data presented as n (%) or mean ± SD</i>		

Table 2: Cumulative pain score in term of VAS score

Time	VAS score		P value
	Group A (FICB) * n = 30	Group B (Fem 3 in 1) * n = 30	
At rest	3.67 ± 2.17	3.10 ± 1.73	0.109
On movement	5.73 ± 2.43	5.67 ± 1.99	0.073
At 0 min †	3.97 ± 1.90	4.20 ± 1.73	0.200
After 5 min	3.77 ± 1.80	2.50 ± 1.72	0.589
After 10 min	2.83 ± 1.78	1.90 ± 1.40	0.335
After 15 min	2.63 ± 1.87	1.60 ± 1.25	0.101
After 20 min	2.03 ± 1.99	1.33 ± 1.16	0.026
After 30 min	1.03 ± 1.71	0.50 ± 0.86	0.001

Data presented as mean ± SD; P < 0.05 considered as significant

with Pearson Chi-square.

Table 3: Total VAS reduction from baseline according to time

Time	Pain reduction (VAS)		P value
	Group A (FICB) * n = 30	Group B (Fem 3 in 1) * n = 30	
0 to 5 min	0.20 ± 0.484	1.7 ± 0.75	0.011
0 to 10 min	1.13 ± 0.82	2.3 ± 1.06	0.260
0 to 15 min	1.33 ± 0.80	2.6 ± 1.13	0.082
0 to 20 min	1.93 ± 1.11	2.87 ± 1.43	0.558
0 to 30 min'	2.93 ± 1.26	3.7 ± 1.49	0.795

Data presented as mean ± SD; P < 0.05 considered as significant

body weight given over a 2-3 min duration after careful negative aspiration of blood to rule out inadvertent vascular puncture. No vascular punctured avoid complication such as not exceeding maximum dose of 3 mg / kg, careful aspiration to detect intravascular before injecting the local anesthetic and the total volume of local anesthetic given in titration for 5 min duration. Baseline pain score at rest and upon movement recorded using visual analogue scale (VAS) at interval of 5 min till 30 min post block and prior to positioning.

Statistical analysis

Table 4: Types of fractures [n (%)]

Part of femur involved	Group A (FICB) * n = 30	Group B (Fem 3 in 1) * n = 30
Neck of femur	4 (13.3)	1 (3.3)
Proximal	3 (10)	5 (16.7)
Midshaft	14 (46.7)	13 (43.3)
Distal	5 (16.7)	6 (20.0)
Multiple	4 (13.3)	5 (16.7)

Based on a previous study by Newman et al [7], the sample size was calculated based on reduction of visual analogue score with score 3.7 ± 2.6 , $\alpha = 0.05$ and power of study 80%. The data were analyzed with Statistical Package for Social Sciences 22.0 (SPSS, Inc., Chicago, IL, USA) and were expressed as mean ± SD or number of patients. Pain score and analgesic requirements were analysed using independent t-test. A $P < 0.05$ was considered statistically significant. Categorical data were analysed

3. RESULTS

A total of 60 patients were recruited for this study over a one-year period (Figure 1). The demographic data were comparable between Group A and Group B (Table 1).

Comparing the mean VAS at rest and upon movement (Table 2), the baseline VAS at rest and upon movement were not significantly different (FICB 3.67 ± 2.17 , FNB

3.10 ± 1.73 , $P = 0.109$) and (FICB 5.73 ± 2.43 , FNB 5.67 ± 1.99 , $P = 0.073$). We found out that femoral 3 in 1 nerve block is more significant and effective in reducing VAS at 20 min' post block (1.7 ± 0.75 , $P = 0.011$).

The pain score at 20 and 30 min' much lower in Group B (1.33 ± 1.16 , $P = 0.026$, 0.50 ± 0.86 , $P = 0.001$) and this is evidence by lower rescue dose of fentanyl (10.83 ± 29.13 , $P = 0.018$) to treat pain in this group (Table 3).

Most of fracture site in this study involved the midshaft and distal part of femur (Table 4).

Both techniques show similar efficacy at 30 min' post block probably because of the volume of ropivacaine used is large and not statistically different, (FICB 34.67 ± 6.29 , FNB 36.67 ± 5.47 , $P = 0.132$ (Table 5).

4. DISCUSSION

This study aimed to determine superiority of either the USG 3-in-1 FNB or single blind fascia iliaca compartment block as analgesia method in patient with femur fracture prior positioning for SA.

We found out that femoral 3 in 1 nerve block is more significant and effective in reducing VAS at 20 min' post

Table 5: Volume of Ropivacaine 0.375% used and total dose rescue fentanyl

Dose of drug	Group A (FICB)* n = 30	Group B (Fem 3 in 1)* n = 30	P value
Ropivacaine used (mL)	34.67 ± 6.29	36.67 ± 5.47	0.132
Rescue analgesic Fentanyl (µg)	23.33 ± 35.92	10.83 ± 29.13	0.018

Data presented as mean ± SD; P < 0.05 considered as significant

block. This result shows that ultrasound guided femoral 3 in 1 block reduced pain score more effectively after the block as compared to the single shot blind technique of fascia iliaca compartment block. This is somewhat similar to finding by the Newman et al.⁷ However, Ghimire et al⁸ found out that VAS was lower in FICB. The possible explanation lies in their method in performing femoral nerve block, where it was done blind based on anatomical marking. This approach doesn't ensure the success rate of anesthetising the femoral nerve. Compared to our approach, we utilized the direct visualization of femoral nerve with ultrasound which ensure higher success rate to block the intended nerve. With sound knowledge of sonoanatomy allows deposition of local anesthetic near the perineural sheath. Use of ultrasound can result in more complete blockade of the femoral nerve.⁹

Another explanation lies in the type of fracture involved. Most of fracture site in this study involved the midshaft and distal part of femur, where main innervation of femoral shaft comes from the femoral nerve. Thus, it is more likely the femoral 3 in 1 is more effective as it is done with use of ultrasound permitting earlier onset of ropivacaine used in this study. Result obtained could probably be different if fascia iliaca also performed with ultrasound guidance.¹⁰ There is possibility of difference outcome between supra inguinal and infra inguinal approach of fascia iliaca compartment block.

Our study also shows faster onset of pain relief in Group B as evidence by higher VAS reduction at least after 5 min post block. This could probably explain why VAS was lower in this group at 20 and 30 min' post block. Osborne et al¹¹ also found out similar findings where ultrasound guided femoral 3 in1 block provide faster onset of anesthesia. They recommend to use this type of block if speed of onset is the primary objective before induction of anesthesia. This technique is more suited for patient plan for SA, as this block can provide faster onset analgesia prior positioning if time is an issue. It has the potential to be useful in acute pain management of femoral bone fracture in patient presented to emergency

department. It may reduce the dose of nonsteroidal anti-inflammatory drug or opioids needed to relief pain, thus reducing side effects related to the drug. Whereas fascia iliaca compartment block using blind technique and proper plane is presumably identified after felt twice of loss of resistance technique. The local anesthetic placed in the compartment should be spread cephalad along the fascia plane to reach the femoral plexus

and exert its action. Thus, the onset is slower compared to femoral 3 in 1 block using ultrasound. This finding contradicts the findings by the Capdevila et al¹² where they found out fascia iliaca provided much faster and more consistent simultaneous block of the lateral femoral cutaneous nerve and femoral nerve.

Based on our findings, we demonstrated that both techniques significantly reduce VAS from baseline at 30 min' post block. Thus, both techniques are useful for pain relief in patients with femur fracture as it reduces pain score more than 2 from baseline. Although our findings suggest that there is no statistical different in between of the groups at 30 min' post block, the result could possibly be different if comparison made with both block uses blind technique. This could explain why result has been inconsistent with the other study. The use of ultrasound machine and special blunted needle (Plexufix® 24G x 2", B Braun Melsungen AG 34209 Melsungen Germany) might considerably increase the success rate of femoral 3 in 1 block and fascia iliaca compartment block respectively. The use of insulated stimulating needle (Stimuplex® D Plus 22g x 2", B Braun Melsungen AG 34209 Melsungen Germany) has improved the needle tip visualization under the ultrasound guidance however better insulated needle with better echogenicity might influenced the outcome.¹³ User experiences in using also could be determining factor, however it was not studied in this study. Clinical experiences might influence the time used to place block in the femoral 3 in 1 group. Uncertainty of sonoanatomy might also influence the success rate and complication of femoral 3 in 1 block.

Apart from that, both techniques show similar efficacy at 30 min' post block probably because of the volume of ropivacaine used is large. In the other study, volume of local anesthetic used has been varied and types of local anesthetic used also differ. If faster onset local anesthetic such as lignocaine is used, it may result in faster onset of fascia iliaca block as what been found by Ghimire et al⁸, where they used lignocaine 1.5% as the main anesthetic. Theoretically, a large volume of local anesthetic is needed for it to spread and reach intended nerve plexus.

Both groups don't show any significant side effects or signs of acute local anesthetic toxicity. This is because although the volume of ropivacaine used is high, the total dose per kg doesn't exceed the toxic dose of 3 mg / kg. We calculated and gave the dose depending on the patient's body weight. Ultrasound guidance avoided puncturing the neurovascular bundle and fascia iliaca block performed at a distance from the important vascular structure.

We concluded that both techniques provide acceptable reduction in VAS as mean difference of VAS at 30 min' is not significant. If time is not an issue to wait for the block properly worked out, any of the techniques can be applied. However, if equipment such as ultrasound not available as well as expertise, then the fascia iliaca block is preferable. Fascia iliaca block can be done even by the any other trained health care provider without anesthetic bac kg round such as nurses. The success rate was quoted more than 70% which is more than adequate^{2,3} and it is easy, inexpensive and proven safe to be done even at prehospital level.¹

5. CONCLUSION

The ultrasound guided femoral 3 in 1 block and fascia iliaca block are equally effective in reducing VAS in femur fracture especially in fracture shaft of femur. If rapid onset is the objective, the ultrasound guided femoral 3 in 1 is preferable, however, the fascia iliaca block can be done if ultrasound not available.

6. Data availability

The numerical data generated during this research is available with the authors.

7. Acknowledgement

We gratefully thank Faculty, Department of Anesthesiology & Intensive Care, School of Medical Sciences & Hospital, Health Campus, Universiti Sains Malaysia, 16150 Kubang Kerian, Kelantan, Malaysia for their full cooperation during the conduct of this study

8 Conflict of interest

The study utilized the hospital resources only, and no external or industry funding was involved.

9. Authors' contribution

RHMZ, IWMR, SCO: Conception, design, execution, analysis, interpretation of the data, drafting and final approval of manuscript

WMZWH, UE, MAI, PS: Critical revision of article, statistical analysis, final approval of article

10. REFERENCES

- Lopez S, Gros T, Bernard N, Plasse C, Capdevila X. Fascia iliaca compartment block for femoral bone fractures in prehospital care. *Reg Anesth Pain Med.* 2003;28(3):203-7. PMID: 12772137 DOI: 10.1053/rapm.2003.50134
- Obideyi A, Srikantharajah I, Grigg L, Randall A. Nurse administered fascia iliaca compartment block for pre-operative pain relief in adult fractured neck of femur. *Acute Pain.* 2008;10(3-4):145-9. DOI: 10.1016/j.acpain.2008.05.014
- Randall A, Grigg L, Obideyi A, Srikantharajah I. Fascia Iliaca compartment block: A nurse-led initiative for preoperative pain management in patients with a fractured neck of femur. *J Orthop Nurs.* 2008;12(2):69-74. DOI: 10.1016/j.joon.2008.07.007
- McLaren AD, Stockwell MC, Reid VT. Anaesthetic techniques for surgical correction of fractured neck of femur. A comparative study of spinal and general anaesthesia in the elderly. *Anaesthesia.* 1978 Jan;33(1):10-14. PMID: 626331 DOI: 10.1111/j.1365-2044.1978.tb08270.x
- Winnie a P, Ramamurthy S, Durrani Z. The inguinal paravascular technic of lumbar plexus anesthesia: the "3-in-1 block". *Anesth Analg.* 1973;52(6):989-96. PMID: 4796576
- Dalens B, Vanneville G, Tanguy A. Comparison of the Fascia Iliaca Compartment Block with the 3-in-1 Block in Children. *Anesth Analg.* 1989;69:705-13. PMID: 2589650
- Newman B, McCarthy L, Thomas PW, May P, Layzell M, Horn K. A comparison of pre-operative nerve stimulator-guided femoral nerve block and fascia iliaca compartment block in patients with a femoral neck fracture. *Anaesthesia.* 2013 Sep;68(9):899-903. PMID: 23789738 DOI: 10.1111/anae.12321
- Ghimire A, Bhattarai B, Koirala S, Subedi A. Analgesia before performing subarachnoid block in the sitting position in patients with proximal femoral fracture: A comparison between fascia iliaca block and femoral nerve block. *Kathmandu Univ Med J.* 2015;13(50):152-5. PMID: 26643833 DOI: 10.3126/kumj.v13i2.16789
- Möller T, Benthous S, Huber M, Bentrup I, Schofer M, et al. A Randomized and Observer Blinded Comparison of Continuous Femoral Block and Fascia Iliaca Compartment Block in Hip Replacement Surgery. *J Anesth Clin Res.* 2011;S1:005. DOI: 10.4172/2155-6148.S1-005
- Hebbard P, Ivanusic J, Sha S. Ultrasound-guided supra-inguinal fascia iliaca block: A cadaveric evaluation of a novel approach. *Anaesthesia.* 2011;66(4):300-5. PMID: 21401544 DOI: 10.1111/j.1365-2044.2011.06628.x
- Wallace JB, Andrade JA, Christensen JP, Osborne LA, Pellegrini JE. Comparison of fascia iliaca compartment block and 3-in-1 block in adults undergoing knee arthroscopy and meniscal repair. *AANA J.* 2012 Aug;80(4 Suppl):S37-44. PMID: 23248829
- Capdevila X, Biboulet P, Bouregba M, Barthelet Y, Rubenovitch J, D'Athis F, et al. Comparison of the three-in-one and fascia iliaca compartment blocks in adults: Clinical and radiographic analysis. *Anesth Analg.* 1998;86(5):1039-44. PMID: 9585293 DOI: 10.1097/0000539-199805000-00025
- Sviggum H, Ahn K, Dilger J, Smith H. Needle Echogenicity in Sonographically Guided Regional Anesthesia: blinded comparison of 4 enhanced needles and validation of visual criteria for evaluation. *J Ultrasound Med.* 2013;32:143-8. PMID: 23269719 DOI: 10.7863/jum.2013.32.1.143