

CASE SERIES

INTENSIVE CARE

The use of antivenom serum, fresh frozen plasma, and platelet concentrate for management strategy of snakebite related coagulopathy: a case series

Septian Adi Permana¹, Muhammad Markam Shalihin²

Author affiliations:

1. Septian Adi Permana, Lecturer and Staff of Anesthesia and Intensive Therapy, UNS Faculty of Medicine, Dr. Moewardi Hospital, Surakarta, Central Java, Indonesia; E-mail: septianadi03@gmail.com

2. Muhammad Markam Shalihin, Resident of Anesthesia and Intensive Therapy, UNS Faculty of Medicine, Dr. Moewardi Hospital, Surakarta, Central Java, Indonesia; E-mail: shalihinmarkam@gmail.com

Correspondence: Muhammad Markam Shalihin; **E-mail:** shalihinmarkam@gmail.com; **Phone:** +62 823-8288-1515

ABSTRACT

Snakebite is a medical emergency. It can cause local and systemic effects in humans. Different venomous snakes produce different types of venom, which can cause a variety of symptoms and complications. The scarcity of anti-snake venom serum (SABU) in Indonesia encourages alternative administration strategies to patients, namely suboptimal doses or subdose.

Three cases of adult patients with a history of snakebite and diagnosed with snakebite grade III were reported. The patient underwent initial antivenom therapy using suboptimal doses of anti-snake venom serum (SABU) due to the scarcity of SABU and fresh frozen plasma (FFP) and thrombocyte concentrate (TC) transfusions as well as initial emergency management and routine blood tests and coagulation function. Evaluation was done daily of clinical improvement and coagulation function.

This case series proves that administration of suboptimal antivenom therapy, when combined with additional FFP and TC transfusions, coupled with appropriate supportive care and patient monitoring can result in good outcome in patients.

Key words: Anti-snake Venom Serum; FFP; Snakebite; Thrombocyte Concentrate; Toxin

Citation: Permana SA, Shalihin MM. The use of antivenom serum, fresh frozen plasma, and platelet concentrate for management strategy of snakebite related coagulopathy: a case series. *Anaesth. pain intensive care* 2023;27(6):750–756; DOI: [10.35975/apic.v27i6.2250](https://doi.org/10.35975/apic.v27i6.2250)

Received: July 27, 2023; **Revised:** October 17, 2023; **Accepted:** October 17, 2023

1. INTRODUCTION

Snake-bite is a neglected public health problem in many tropical and subtropical countries. Approximately 5.4 million snake bites occur each year, resulting in 1.8 to 2.7 million cases of envenomization (snake-bite poisoning).¹ There have been about 81,410 to 137,880 deaths and about three times as many amputations and other permanent disabilities each year.¹

Most of the snake-bites occur in Africa, Asia, and Latin America. In Asia up to 2 million people are bitten by snakes each year, whereas in Africa an estimated 435,000 to 580,000 snakebites annually require

treatment.¹ Snake-bite envenomization affects women, children, and farmers in poor rural communities in low and middle-income countries.¹ The burden is highest in countries where health systems are the weakest and medical resources are scarce.¹

Snakebite and envenomization can cause an acute medical emergency involving severe muscular paralysis which can compromise breathing, or cause a bleeding disorder that can lead to fatal hemorrhage and permanent kidney failure, and severe local tissue damage which can lead to permanent disability and limb amputation.¹

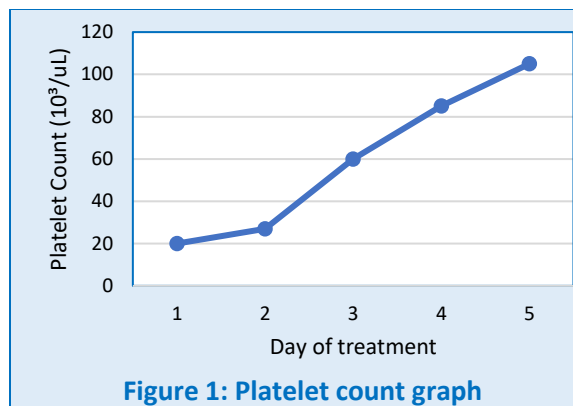
Most deaths and serious complications from snake bites can be completely prevented by timely antivenom administration. A high-quality snake antivenom is the most effective treatment for preventing or reversing most of the venomous effects of a snakebite.¹ However, access to and use of locally produced antivenom serum, called Serum Anti Ular Bisa (SABU) in Indonesia, is still limited. The transfusion of thrombocyte concentrates (TC) and/or fresh frozen plasma (FFP) to compensate the resource limitation of SABU can provide advantages in the form of its tolerable nature and easy to predict its therapeutic index. The use that can also be repeated several times is an advantage that can be considered for using blood component products to manage coagulopathies.

2. CASE SERIES

2.1. Case-1

The first case was a 49-year-old man with a grade III snake bite in the right dorsum pedis region. The patient complained of leg pain after being bitten by a snake. Four days before admission, the patient's leg was suddenly bitten by a snake when the patient was looking for fish in the river. The biting snake is reported to be green. After being bitten, the patient felt pain in the bitten area and observed swelling in the legs from the thighs, testicles, and penis. The patient was taken to a local hospital and given pain medication and anti-venom, then was hospitalized for 4 days. Due to limited facilities, the patient was referred. Examination of the patient's initial vital signs within normal limits. Physical examination reveals a clear airway and adequate spontaneous breathing, no abnormality was found on pulmonary heart examination, and adequate nutrition.

On examination of the local status in the right pedis region, there was edema with fang marks on the dorsum pedis (not accompanied by bullae), tenderness, and digits I to V oxygen saturation of 99-100%. In the right cruris and femur region, edema (without bullae) was observed with a posterolateral hematoma measuring 4x3cm and tenderness. In the genital region, there was edema of the scrotum and penis. On a routine blood test, leukocytosis, prolonged PT and aPTT, and abnormal INR as well as thrombocytopenia and anemia were found.



The initial treatment given in the emergency room was fluid administration using ringer lactate (RL) 1500 ml/24 h, injection of metamizole 1 g/8 h, omeprazole 40mg/12 h, ampicillin 1 g/8 h and Anti Tetanus Serum (ATS) 1500 IU. The patient was admitted to the High Care Unit (HCU) and programmed for another 1 vial of SABU injection in DW5 500 ml/8 h, routine blood evaluation, PT, aPTT per 24 h and 4 units of TC transfusion as well as observation for signs of compartment syndrome, hemotoxic and neurotoxic signs (Table 1).

Twenty-four hours after the initial therapy (administration of SABU and TC 4 units transfusion, specifically), reddish-yellow urine was observed. Prolonged PT and aPTT on blood laboratory results and abnormal INR were also obtained. Platelets are still low. Patients were programmed to continue therapy, including RL 1500/24 h, inj. metamizole 1 g/ 8 h, omeprazole 40 mg/12 h, ampicillin 1 G/8 h and 1 vial of SABU in DW5 500 ml/8 h).

Even after 48 h, urine was found to be reddish in color accompanied by abnormal laboratory results: prolonged PT and aPTT, abnormal INR; but platelets count started to increase. Patient was programmed to continue previous therapy. Signs of bleeding, e.g., purpura, bleeding gums, dark stools, and hematemesis were denied.

After 72 h of treatment, the urine color started to clear and laboratory results (platelets, PT, aPTT, and INR) started to improve. Patients were programmed to continue therapy. Signs of bleeding were absent.

Table 1: Patient's laboratory results

Test	Normal values	D-1	D-2	D-3	D-4	D-5
Hb (g/dl)	Male:13.0-17.0 Female:11.5-15.5	15.8	9.3	11.2	11.6	10.6
PT (sec)	10 to 13	18.2	19.3	24.1	16.0	15.2
aPTT (sec)	30-40	41.2	42.4	43.8	36.5	35
INR	≤ 1.1	1.140	1.580	2.080	1.250	1.220

After 96 h, urinary complaints disappeared and laboratory results were close to normal. Patient continued the therapy. Signs of bleeding disappeared.

2.2. CASE-2

Our second case, a 40-year-old man with a grade III snakebite on his hand and thrombocytopenia. He initially complained of pain in the right finger after being bitten by a snake on the right finger while cutting grass in the fields. The biting snake was reported to be black. The patient was brought to the local hospital and given an injection of analgesics, antibiotics, and SABU as well as a TC 4 units transfusion. Patient was referred to our hospital. Past medical history was negative, and the patient's initial vital signs were within normal limits. The physical examination was within normal limits, and he had adequate nutrition.

On examination of the right hand, there was edema accompanied by fang marks on the little finger with hematoma, bulla and active bleeding. There was tenderness and a positive passive stretch test with a prolonged CRT. SpO₂ was 99%. On routine blood laboratory investigations, severe thrombocytopenia was observed with prolonged PT, aPTT, and leukocytosis.

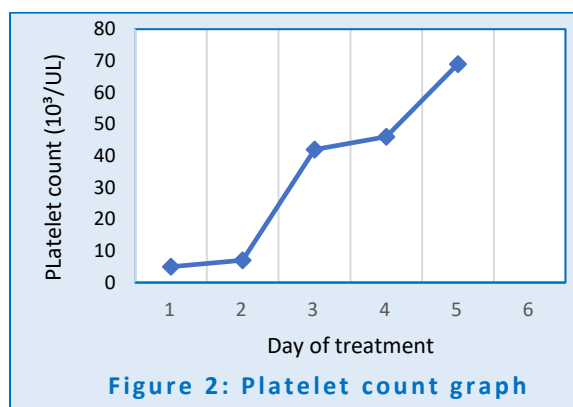
Initial therapy in the emergency room was given RL 1500 ml/24 h, inj. ampicillin 1 g/8 h, metamizole 1 g/8 h and one vial of SABU infusion in DW5/12 h. In the emergency room, bullae aspiration and medication were also carried out and the wound was covered with dry bandage and gauze. The patient was transferred to the HCU and was scheduled to continue TC and FFP transfusion (4 units each), to recheck PT and aPTT every 24 h, and continue SABU infusion. The patient was also educated to elevate the affected hand.

After being given TC and FFP, 4 units each, in the first 24 h of treatment, routine blood and coagulation function tests were still abnormal, although INR was decreased. The patient was consulted for internal medicine due to coagulation disorders. The patient was advised to receive 4 units of FFP and TC transfusions each because the platelets had not reached the target (> 50,000) and INR (< 2) count. The previous therapy was continued.

Apart from coagulation disorder, leukocytosis improved after 24 h of stay in the HCU. The patient did not have a

fever even when in the ER. Procalcitonin levels were checked to be 0.09. The patient's Hb also decreased from the initial value and was examined 24 h and 48 h later. There was no sign of bleeding from anywhere. After 72 h of treatment, improvement of laboratory results was observed. Patient was programmed to continue therapy. Signs of bleeding were absent.

After 96 h of treatment, the laboratory results were found closer to normal. Patient was scheduled to continue therapy.



2.3. CASE-3

Our third case, a 47-year-old woman presented with a grade III snakebite at dorsum of the foot with thrombocytopenia, hyperglycemia, anemia and hyponatremia. The patient complained of pain in the left leg after being bitten by a brown snake in the forest. The patient could not recall the shape of the snake's head. After being bitten, the patient felt nausea. She was taken to a local hospital and given a fluid infusion, analgesics, and was hospitalized. Due to limited SABU stock at the hospital, the patient was referred to our hospital. History of other diseases was denied. Her vital signs were within normal limits. She had clear airways, adequate spontaneous breathing; cardiopulmonary examination was within normal limits, and she had adequate built.

Local examination of the left foot revealed edema accompanied by fang marks and bullae on the dorsum. The foot was tender. SpO₂ was 100%. In the left thigh, there was edema, bullae, and hematoma in the distal

Table 2: Second patient's laboratory results

Test	Normal values	D-1	D-2	D-3	D-4	D-5
Hb (g/dl)	Male:13.0-17.0 Female:11.5-15.5	12.3	10.9	10.3	10.2	11.4
PT (sec)	10 to 13	131.4	57.6	81.7	61.1	43.1
aPTT (sec)	30-40	140	>140	>140	42.4	40.4
INR	≤ 1.1	18.400	6.410	9.660	4.773	3.367

Table 3: Third patient's laboratory results

Test	Normal values	D-1	D-2	D-3	D-4	D-5
Hb (g/dl)	Male:13.0-17.0 Female:11.5-15.5	8.3	6.8	7.1	11.2	12.3
PT (sec)	10 to 13	>300	18.3	300	54.2	23.1
aPTT (sec)	30-40	>300	73.0	140	42.4	40.4
INR	≤ 1.1	140.000	1.480	-	6.408	2.495

anterolateral thigh measuring 4x3 cm accompanied by tenderness.

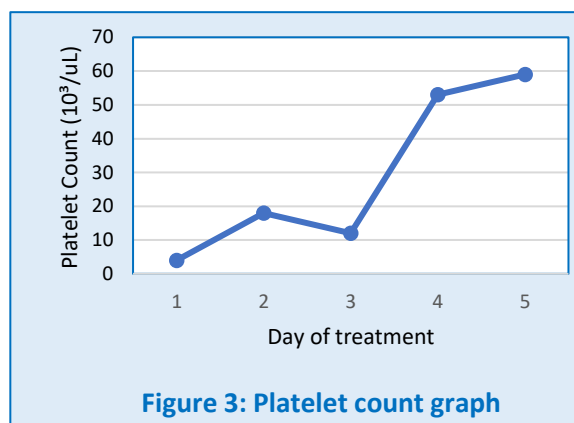
Routine laboratory investigations revealed anemia, thrombocytopenia, hyponatremia, leukocytosis, hyperglycemia, increased PT and aPTT, and abnormal INR. Patients were given saline infusion 1500 ml/24 h, inj metamizole 1 g/8 h, omeprazole 40 mg/12 h, ampicillin 1 g/8 h and ATS 1500 IU. She was admitted to the HCU and instructed to immobilize and elevate the left inferior limb and was recommended one vial of SABU in DW5 500 ml/8 h infusion, injection of human tetanus immunoglobulin 250 mg, metamizole 1 g/8 h, ranitidine 50 mg/12 h, insulin 10 IU (and continued **SP 50 IU** in 50 ml NS at a speed of 5 ml/h), 3 units of Packed Red Cells (PRC) and 3 and 4 units of TC were transfused then consulted the internal medicine. Signs for compartment syndrome, hemotoxic and neurotoxic signs as well as hourly glucose monitoring were monitored.

In the first 24 h of treatment, a persisting hyperglycemia was observed, especially in the first 2 h. An extra insulin injection of 10 IU/h was required to achieve target glucose levels (150-200 mg/dL). Blood glucose control was obtained after 2 extra insulin shots each of 10 IU and continued with an insulin syringe pump. Apidra® (insulin glulisine injection) 6 ml/h and an additional 8 IU if the blood glucose was still high). After 4 h of treatment to control blood glucose, the Apidra syringe pump was continued at a rate of 0.5 ml/h.

There was a worsening anemia with decreased MCV and MCH (78.7 and 25.3 respectively), leukocytosis, improvement of thrombocytopenia, prolonged PT and aPTT, and abnormal INR close to normal. The patient was scheduled for further therapy with infusion of 0.9% NaCl 1500 ml/24 h, inj. metamizole 1 g/8 h, omeprazole 40 mg/12 h, ampicillin 1 g/8 h and ATS 1500 IU. Additional 4 units of PRC and folic acid 800 µg with tab Prorenal 3x1 PO were administered. Signs of spontaneous bleeding, compartment syndrome or signs of hemotoxic or neurotoxic were absent.

After 72 h of treatment, improvement of laboratory results (platelets, PT, aPTT, and INR) were observed. Patient was scheduled to continue therapy. Signs of bleeding disappeared.

After ninety-six hours of treatment, bleeding complaints no longer persisted and laboratory results came closer to normal.



3. DISCUSSION

Snakebite is a medical emergency, which has the potential to be morbid and fatal if it is not recognized, treated, and evaluated promptly. The management of snake bite cases is not much different from other trauma cases, with primary survey getting priority. Accurate and quick identification is the key to the best outcome in these cases.

About 15% of the world's 3,000 snake species are considered dangerous to humans. There are three species of venomous snakes in Southeast Asia, namely Elapidae, Viperidae, and Colubridae; all of which have different venom toxicity and clinical presentation.¹ The snake species that cause the most bites in humans are Elapidae and Viperidae.¹

Snakes from the Elapidae family have a long, thin, dense body shape with fine scales arranged symmetrically on the head.¹ The fangs are used to connect the poison glands with the venom that is released onto the prey. Some of the species in this family are Naja (Cobra), Bungarus (Kraits), Taipan, Acanthophis, Oxyuranus, Pseudechis, Pseudonaja (black and brown snake), and sea snakes.

Snakebite cases can also be divided into venomous and non-venomous. In clinical settings, identification of the two phenomena can be done through relevant history.

Inspection of the bitten area or wound may provide clues. Venomous snakes usually leave bite marks or fang marks like two firm points, while non-venomous snakes have two rows of teeth but do not appear distinct.^{1,2} After identifying the type of snake that bit the patient, the next step is to determine the venom characteristics of the snake.

Venomous snakes are further divided into two groups based on the type of toxin secreted: neurotoxic and hemotoxic. Snakes with neurotoxic venom can present clinical manifestations related to dysfunction of the nervous system. Complaints such as blurred vision, diplopia, to depression of the respiratory system can occur. In snakes with hemotoxic venom, patients may present with manifestations of coagulation disorders (coagulopathy), active bleeding, and multiple organ dysfunction.^{1,2}

Toxins can affect local tissues. Follow-up evaluation of active bleeding, edema, hematoma, or even bullae is important to assess the severity of the toxins' local effect. Nearby lymph nodes can also be evaluated whether there is swelling or not, especially in the area around the snake bite site. Apart from inspection, it can also be evaluated whether there is tenderness felt by the patient in the bite area. Systemic symptoms that can occur after a snake bite varies from mild to severe: nausea, vomiting, abdominal pain, dizziness, and lethargy. These abnormalities are related to the interruption of circulatory and cardiovascular systems due to shock at a more severe degree of snakebite.

The known primary treatment, based on WHO's management of snakebite guidelines, are intravenous antivenom.² General indications for antivenom administration are as follow: hemostatic abnormalities (systemic spontaneous bleeding distant from the bitten area, or coagulopathy marked by INR > 1.2, or thrombocytopenia < 100), neurotoxic sign (ptosis, external ophthalmoplegia, paralysis), cardiovascular abnormalities (hypotension, shock, symptomatic cardiac arrhythmias, acute kidney injury (anuria or abnormal creatinine/urea levels), hemoglobinuria, extensive local swelling (more than half of the bitten limb) within 48 h of bite, and lymphadenopathy.² Anti-venom can be administered intravenously, either by infusion or slow bolus. The WHO approved and recommended antivenom used in Indonesia is SABU. The advocated dose for SABU used in Indonesia is 10 ml diluted in 100 ml of 0.9% NaCl and infused over 30 min, which can be repeated every 6 to 8 h.

It is better to identify the biting snake species because the initial antivenom dose given is variable. Some known species require a conservative amount (such as *Micropechis ikaheka* or New Guinean small-eyed snake that requires 10 ml of antivenom administered

initially) but some other requires a considerable dose, such as *Ophiophagus Hannah* or "king cobra" that requires 100 ml of antivenom administered initially.²

SABU administration can be given 4 h after the bite to prevent complications due to coagulopathy.² However, the availability and access to antivenom in Indonesia is an issue. Due to limited or stock rarity, the patient received insufficient therapy, not according to recommendations by WHO's snakebite management guidelines. In other cases, if the hospital has enough stocks, due to the rarity of snakebite cases the antivenom would expire before it could be used. Hence the need to "conserve" the total stock of SABU in certain hospitals was felt, a strategic option was to adhere to suboptimal dosing while adding another treatment.

It shall also be kept in mind that coagulopathy does not stop immediately even after the administration of SABU (due to anti-venom serum only binding to snake venom that is "free" in circulation). Proteases from the venom can impair the physiological coagulation process.^{6,7} Therefore, it still is necessary to provide additional therapy aimed at improving coagulation function to prevent bleeding and further coagulation disorders.

The treatment for coagulopathy (due to primary causes) are generally anticlotting drugs (anticoagulants, thrombolytics, antiplatelet drugs, or clotting facilitator drug) and blood component such as fresh frozen plasma, procoagulant mixture (cryoprecipitate), thrombocyte concentrate, or whole blood if any above weren't readily available.⁸

The addition of FFP (if not available can also use TC or even whole-blood) transfusion may be considered in patients receiving suboptimal SABU dose or even suspected of having a severe hemotoxic reaction.⁶ The use of additional FFP, based on a recent study in Australia, can be used to achieve rapid control of coagulation function (achieving INR < 2) when given within 4 h of initial administration of SABU.⁹ However, meta-analyses examining FFP administration for VICC (venom-induced consumptive coagulopathy) emphasized that maximum effectiveness of FFP administration can be achieved when administered 6 h post-bite (in patients with active bleeding). There are limited studies addressing the administration of FFP in patients without signs of active bleeding, but it is not recommended to delay FFP specifically in critically ill patients.¹⁰

In the first case, the progress of the patient was relatively well compared to the other two cases. The patient came with complaints of pain in the snakebite area in the right dorsum pedis region accompanied by local edema. After being treated for the first 24 h the symptoms improved, e.g., reduced pain and improved laboratory results

(increased platelets, decreased leukocytes, and increased Hb). PT and aPTT did not improve in the first 24 h. However, clinical signs such as spontaneous bleeding or compartment syndrome were not found. Even so, the urine appeared reddish in color on the first day. Only after 48 to 72 h of treatment with the continued therapy was there a general improvement in PT, aPTT and INR values (in particular INR reached below 2 after 72 h of treatment). These findings were also accompanied by overall clinical improvement in patients indicating optimal therapy was achieved.

When our second patient came to the emergency room, snakebite marks were accompanied by local edema with active bleeding, and the deranged coagulation profile. Initially patient was given 1500 ml/24 h RL infusion, ampicillin, metamizole and SABU drip in DW5/12 h. The wound was covered with dry tulle and gauze as well as a transfusion of TC 4 units and FFP 4 units, recheck PT, aPTT every 24 h and continued SABU infusion. After 24 h, the ongoing bleeding resolved but thrombocytopenia, prolonged PT and aPTT, and abnormal INR still persisted. With regard to this problem, another FFP and TC transfusion of 4 units each was carried out to achieve the targeted therapy (platelet count > 50 and INR < 2). Previous therapy was continued.

In the third case there was thrombocytopenia, impaired coagulation function, hyperglycemia, and severe hyponatremia. The initial therapy given was in the form of infusion of 0.9% NaCl 1500 ml/24 h, metamizole, omeprazole, ampicillin and ATS, and infusion of SABU 1 vial in DW5 500 ml/8 h. Patient was given insulin drip and fast acting extra insulin (Novorapid 8 IU) to control optimal blood glucose level (<200). Furthermore, the patient's blood sugar control was carried out with the care of an internal medicine specialist using Lantus 10 IU once at night and Novorapid 6 IU three times a day. In the first 24 h of treatment, improvements in Hb, platelet count, leukocyte count, coagulation physiology, and blood sodium were observed. Repeated PRC transfusion was carried out due to persisting anemia, and improvement was achieved after 48 h of treatment and a total of 7 units of PRC. Transfusion of 4 units of TC was also carried out in the emergency room and some increase in platelet count was found. Improvement in serum sodium was also obtained after infusion of 0.9 NaCl 1500 ml. Even so, the patient's Hb and coagulation function could not reach the therapeutic target after 48 h of therapy. Clinically the patient appeared well.

From all three cases, it can be said that a suboptimal administration of antivenom only if added with additional transfusion of TC and/or FFP can improve coagulation function and clinical outcomes. However, snakebite management in hospitals still needs to be

carried out by following the ABCDE principles (airway, breathing, circulation, disability, and exposure) with continuous monitoring of hemodynamics and symptoms of the spreading toxins. Adequate pain management is also needed, especially in cases of snakebite accompanied by severe pain that the patient experienced. The use of paracetamol as the first line of painkillers can be given, but if the pain is more intense, opioids can also be added. The use of NSAIDs is not recommended because it can increase the coagulopathic effect that occurs in cases of snake bites.² The use of broad-spectrum antibiotics as prophylaxis can be given.^{1,2}

4. CONCLUSION

The case report series reviews the importance of early and appropriate intervention in the management of snake-bite cases. Therapeutic SABU in suboptimal doses with the aid of fresh frozen plasma and thrombocyte concentrate transfusions have been shown to be beneficial for the patient and hospital to conserve the rare stock of SABU. Immediate identification of the snake species and administration of appropriate antivenom therapy and replacement of coagulation components shall be considered. Additionally, supportive care and patient monitoring are essential in ensuring optimal outcomes.

5. Conflict of interest

Authors declare no conflict of interest, and no external or industry funding was involved.

6. Authors' contribution

All authors equally contributed in the conduct of this case series and preparation of the manuscript.

7. REFERENCES

1. World Health Organization. Fact sheet of Snakebite envenoming. WHO; 2019. Available from: <https://www.who.int/news-room/fact-sheets/detail/snakebite-envenoming>
2. WHO. Management of snakebites (WHO 2nd Ed) 2016. 2016;vi, 140 p. Available from: <https://apps.who.int/iris/handle/10665/249547>
3. Panggabean M, Solihat Y. Post-General Anesthesia Angioedema after General Anesthesia. Solo J Anesth Pain Crit Care. 2022;2(1). DOI: [10.20961/soja.v2i1.59185](https://doi.org/10.20961/soja.v2i1.59185)
4. Al Masroori S, Al Balushi F, Al Abri S. Evaluation of Risk Factors of Snake Envenomation and Associated Complications Presenting to Two Emergency Departments in Oman. Oman Med J. 2022 Mar 22;37(2):e349. [PubMed] DOI: [10.5001/omj.2022.46](https://doi.org/10.5001/omj.2022.46)
5. Costello RA, Nehring SM. Disseminated Intravascular Coagulation. [Updated 2023 Jan 20]. In: StatPearls [Internet]. Treasure Island (FL): StatPearls Publishing; 2023. Available from: <https://www.ncbi.nlm.nih.gov/books/NBK441834/>

6. Zeng L, Liang Q, Liang Z, Han J, Wu M, Liu R, et al. Effectiveness of clotting factor replacement therapy after antivenom treatment on coagulopathic envenomation following green pit viper bites: a retrospective observational study. *BMC Emerg Med.* 2022 Jan 19;22(1):9. [PubMed] DOI: [10.1186/s12873-022-00569-w](https://doi.org/10.1186/s12873-022-00569-w)
7. Nanjaraj ANU, Yariswamy M, Joshi V, Nataraju A, Gowda TV, Vishwanath BS. Implications of phytochemicals in snakebite management: present status and future prospects. *Toxin Rev.* 2014;33(3):60-83. DOI: [10.3109/15569543.2013.854255](https://doi.org/10.3109/15569543.2013.854255)
8. Hofer S, Schlimp CJ, Casu S, Grouzi E. Management of Coagulopathy in Bleeding Patients. *J Clin Med.* 2021 Dec 21;11(1):1. [PubMed] DOI: [10.3390/jcm11010001](https://doi.org/10.3390/jcm11010001)
9. Isbister GK, Buckley NA, Page CB, Scorgie FE, Lincz LF, Seldon M, et al. A randomized controlled trial of fresh frozen plasma for treating venom-induced consumption coagulopathy in cases of Australian snakebite (ASP-18). *J Thromb Haemost.* 2013 Jul;11(7):1310-8. [PubMed] DOI: [10.1111/jth.12218](https://doi.org/10.1111/jth.12218)
10. Maduwage K, Isbister GK. Current treatment for venom-induced consumption coagulopathy resulting from snakebite. *PLoS Negl Trop Dis.* 2014 Oct 23;8(10):e3220 [PubMed] DOI: [10.1371/journal.pntd.0003220](https://doi.org/10.1371/journal.pntd.0003220)