

ORIGINAL RESEARCH

PAIN MANAGEMENT

Effect of caudal epidural adhesiolysis plus steroid injections on pain and daily activities among chronic lumbar disc herniation patients; an observational study

Trianggoro Budisulistyo¹, Amin Husni², Dodik Tugasworo Pramukarso³,
Dwi Pudjonarko⁴

Author affiliation:

1. Trianggoro Budisulistyo, Department of Neurology, Pain and Minimally Invasive; Faculty of Medicine, Diponegoro University/ Dr. Kariadi Hospital Semarang- Indonesia; E-mail: trianggoro.b@gmail.com; ORCID: {0000-0001-8085-5030}
2. Amin Husni, Department of Neurology, Neuroanatomy and Movement Disorder; Faculty of Medicine Diponegoro University/ Dr. Kariadi Hospital Semarang- Indonesia; E-mail: husni.amin@gmail.com
3. Dodik Tugasworo Pramukarso, Department of Neurology, Vascular and Neuroimaging; Faculty of Medicine Diponegoro University/ Dr. Kariadi Hospital Semarang- Indonesia; E-mail: dodik_tugasworo@yahoo.com; ORCID:{0000-0001-6193-5828}
4. Dwi Pudjonarko Department of Neurology, Pain and Neuroimaging; Faculty of Medicine Diponegoro University/ Dr. Kariadi Hospital Semarang- Indonesia; E-mail: dr.onang@yahoo.com

Correspondence: Trianggoro Budisulistyo, E-mail: trianggoro.b@gmail.com; Phone: +62248443239; Mobile: +62811272984

ABSTRACT

Background & Objective: The management of lumbar disc herniation (LDH) may involve the surrounding tissues, and attract neovascularization facilitated macrophage aggregates. Epidural triamcinolone might have a half-life ranging from 10–31 days; 80 mg methylprednisolone might improve the pain up to 1 week. The higher doses of steroids will lead to adrenal cortex suppression and osteopenia. We evaluated the effect of treatment with 1500 international unit (IU) hyaluronidase followed by 20 mg triamcinolone at 2 weeks, and 3 and 6 months follow-up.

Methodology: We enrolled seven males (38.9%) and 11 females (61.1%) with mean age 44 ± 23 y in the study. Eight (44.44%) subjects were younger than 51 y old, whereas the 10 (55.56%) subjects were ≥ 51 y old. Twelve (66.7%) subjects had had a bulged disc, and 6 (33.3%) subjects had disc protrusion. We injected 1500 international unit (IU) hyaluronidase followed by 20 mg triamcinolone at the site of disc lesion. Pain scores were measured with NRS scale and Oswestry Disability Index (ODI) scores at 2 weeks, and 3- and 6-months follow-up.

Results: The NRS score improved at 2 weeks, 40% to 71.43%, at 3 months 60% to 100%, and 6 months 80% to 100%. And the Oswestry Disability Index (ODI) score was improved at 2 weeks from 23.5% to 68.18%, at 3 months from 39.13% to 100%, and at 6 months 82.35% to 100%. A significant association was observed between age older than 50 y old and ODI scores at 2 weeks followed up.

Conclusions: The intra-epidural 1500 IU hyaluronidase before triamcinolone brings better results even though using a lower dose of triamcinolone. This approach showed the lower-cost better pain scores as compared to the routine use of heavy doses of triamcinolone for managing bulged and protruding LDH.

Abbreviations: ACTH: Adrenocorticotrophic hormone; CRH: Corticotropin releasing hormone; CSF: Cerebrospinal fluid; HPA: Hypothalamus-Pituitary-Adrenal; ESI: Epidural steroid injection; LDH: Lumbar disc herniation; MRI: Magnetic resonance imaging; NRS: Numerical Rating Scale; ODI: Oswestry Disability Index; TNF- α : Tumor necrosis factor-alpha; VAS: Visual analogue scale

Key words: Bulged disc; Disc protrusion; Lumbar disc herniation; NRS; ODI; Caudal epidural; Adhesiolysis

Citation: Budisulistyo T, Husni A, Pramukarso DT, Pudjonarko D. Effect of caudal epidural adhesiolysis on pain and daily activities among chronic lumbar disc herniation patients. *Anaesth. pain intensive care* 2022;26(6):198–203.

DOI: [10.35975/apic.v27i2.2184](https://doi.org/10.35975/apic.v27i2.2184)

Received: Sep 06, 2022; **Reviewed:** Oct 09, 2022; **Accepted:** Oct 21, 2022

1. INTRODUCTION

Lumbar disc herniation (LDH) has many challenges regarding the management of treatment, whether to focus on the symptoms or the lesion site problems. Conservative treatment can relieve sciatica at 1–4 y of follow-up.^{1,2} Herniated discs might be accompanied by release of inflammatory mediators from the surrounding tissues. Neovascularization and facilitated macrophage transport can double the inflammatory mediators by about 50–70%. So due to the disc materials from herniated discs, the inflammatory mediators might be found inside the epidural space too.³ Radiology images might classify the herniated disc into stages, such as: bulged (stage I); protruded (stage II); extruded (stage III), and sequestered (stage IV) disc.⁴ The management might be concerned with the structural changes (stage II, III, or IV) or only with an inflammatory event (stage I). Conservative treatment for relieving pain due to inflammatory mechanism includes analgesics and anti-inflammation drugs. It might reduce the rate of surgeries in the short term, as the structural changes tend to mechanical compression problems leading to hypersensitization too.⁵ The epidural steroid injections offer a better outcome than oral analgesic medication.⁴

Epidural steroid injections (ESI) are being used worldwide for treating radiculopathy syndromes, offering pain improvement among chronic back pain by at least 50% or more.⁶ Pain improvement is commonly monitored by pain scales, e.g., Visual Analog Scale (VAS), Wong-Baker Faces Scale, or Numerical Rating Scale (NRS). Among these, the NRS seems to be so common as it simply measures pain intensity by classifying mild (1-3), moderate (4-7), or severe (8-10) pain. We chose the NRS because it is more responsive, more sensitive and superior compared to the VAS.⁷ Daily activities were followed up by observing Oswestry Disability Index (ODI) score.⁸

Whether the steroids suppress the ectopic discharge from injured nerves, or the C fibers nerve conduction is decreased; the underlying mechanism remains not fully understood. These could inhibit leukocytes that are affiliated with inflammatory events, local site tissue edema, deposition of fibrin, capillary vasodilatation, blocking of phagocytosis and leukocyte aggregation. The pro-inflammatory substances, lymphokines, and chemotactic molecules presented on the endothelial cell might be inhibited. This mechanism of action can minimize the opportunity of endothelial cell injuries. Triamcinolone acetonide is a soluble glucocorticoid with a shorter time duration than systemic ones. It means as long as the procedure technique is proper, the potential for side effects could be minimized.^{9,10}

Percutaneous epidurolysis or adhesiolysis is used for releasing the sticky structures surrounding the herniation compressed site, so that the steroid and local anesthetic solution might reach the structures of the origin of the pain. It has recently been shown to improve pain improvement in post-spinal surgical pain, canal stenosis, or advanced stage disc herniation. There is moderate or Level II evidence for percutaneous adhesiolysis when treated with central spinal canal stenosis.¹¹ The technical procedure commonly uses hyaluronidase or 10% hypertonic saline. We applied 20 mg triamcinolone accompanied by intra-epidural hyaluronidase. Protruded and extruded discs might not show an improvement in pain.¹² Several inflammatory factors such as: macrophages, source of chemokines and matrix metalloproteinases (MMPs), cyclooxygenase-2 (COX-2) and tumor necrosis factor-alpha (TNF- α) are found in herniated disc site injury.^{13–16} Based on that chronic LDH might be accompanied by adjacent fibrotic changes inside the spinal canal. The principle of the epidurolysis technique is to separate adhesions and manage the inflamed site of lesions. Normal saline can flush inflammation mediators collected inside the epidural space, so could bring improvement during follow up until 6 months.

We analyzed the association between hyaluronidase administration followed by epidural triamcinolone injection, to assess the improvement of pain and daily activity (ODI scores) among stage 1 (bulged) and stage 2 (protruded) of LDH.

2. METHODOLOGY

All subjects were hospitalized in Dr. Kariadi Hospital Semarang, Indonesia, and were covered by the national insurance health system. Eighteen subjects who suffered from bulged or protruded discs at lumbar levels were involved in this study. Seven were males and 11 females, with an age range of 21–67 (mean 44 ± 23) y old. Eight subjects were younger than 51 y (44.44%), whereas 10 were more than 51 y (55.56%) (Table 1).

Ethical Approval was obtained from Health Research Ethics Committee Dr. Kariadi Hospital Semarang Indonesia: No. 1015/EC/KEPK-RSDK/2022, dated 17 January 2022. All subjects were briefed regarding caudal epidural adhesiolysis technique to treat their chronic LDH syndrome. The benefits and potential complications were explained, then signed informed consent was obtained.

The patient lied prone on the table and by posteroanterior fluoroscopic view we identified the sacral cornua and the gap between them as sacral hiatus. After aseptic precautions, 2 mL of 2% lidocaine was injected as local anesthesia and followed by insertion of 18G Tuohy epidural needle. It was inserted until the tip reached a

level of the third sacral vertebral body and was confirmed with fluoroscope to avoid dural sac puncture. If a blood vessel was punctured, the needle was withdrawn a few mm, and then the solution was injected. Two mL of the contrast Iohexol 300 was injected to visualize “Christmas Tree” pattern of sacral nerve roots inside epidural space. Hyaluronic acid 1500 international unit (IU) was diluted with normal saline 0.9% to make 10 mL and injected. The drugs injected might ascend to reach higher up and fill the space without obstruction or block. By leaving for 10 min the hyaluronidase is spread as much as it gets, then followed by 4 mL of triamcinolone 20 mg plus lidocaine.^{17,18} Then 3–4 mL of normal saline was pushed for the flushing purpose.¹⁹

All subjects were kept in the recovery room for at least 30 min to monitor any complications or side effects. The antibiotic prophylaxis was administrated with Inj. Cefazolin 1 G, followed by Inj. Levofloxacin 500 mg per day for 4 days. Thiamine 50 mg/12 h, vitamin B12 one tablet BID, and folic acid were prescribed routinely and the patients were followed-up for 6 months. Whereas, paracetamol was given 500 mg 8 hourly for 5 days only as an analgesic drug for needle insertion injury. All subjects were followed up with assessment of pain intensity (NRS) and daily activities (ODI) at 2 weeks, 3 months, and 6 months. Two weeks of follow-up was suggested by a previous study.²⁰ Subjects maintained personal physical treatments by lying on the bed with knees flexed and then making the external rotation to the right–left 30 times counted 4 times daily. Thus, lower trunk rotation might treat the musculoskeletal or supported tissues involved, which concerns a chronic state of lower back pain. It also can be helping to adhesion tissues flossed within the epidural space.

3. RESULTS

Eleven females (61.1%) and 7 males (38.9%) were followed-up in this study. Eight (44.4%) were younger than 50 y, whereas 10 subjects (55.6%) were older than 50 y (Table 1). The magnetic resonance imaging (MRI) showed that 11 (61.1%) were affected by more than one lesions, while 7 (38.9%) subjects had only one site of LDH (Table 1). Bulged disc or stage 1 disc herniation was observed in 12 (66.7%) subjects; while 6 (33.3%) subjects presented with protrusion or stage 2 disc herniation. All subjects observed pain improvement concerning the NRS score at 2 weeks (40–71.43%), 3 months (60–100%), and 6 months (80–100%) post-surgery (Figure 1).

ODI score improvement was at 2 weeks (23.5–68.18%), 3 months (39.13–100%), and 6 months (82.35–100%) post-surgery (Figure 2).

Table 1: Characteristics of the participants (n = 18)

Variable	Numerical value
Gender	
Male	7 (38.9)
Female	11 (61.1)
Age (y)	21–67 (mean 44 ± 23)
• ≤ 50	8 (44.44)
• 50	10 (55.56)
Involved level	
• 1 level	7 (38.89)
• > 1 level	11 (61.11)
<i>Data presented as n (%) or Range (mean ± SD)</i>	

The paired sample t-test observed good results among subjects after epidurolysis in comparison to the baseline NRS and ODI score. The NRS as well as ODI scores showed improvement at 2 weeks, 3 months and 6 months.

There was no significant difference in pain improvement among the younger than 51 y old or more than 51 y old. However, there was a significant relationship between

Table 2: Subject's gender, levels involved, and age.

No.	Gender	Lesion sites	Age (y)
1.	F	Bulged L5-S1	67
2.	M	Bulged L4-5	21
3.	F	*Protruded L4-5, L5-S1	50
4.	F	Bulged L5-S1	35
5.	M	*Bulged L4-5, L5-S1	51
6.	F	*Bulged L4-5, L5-S1	54
7.	M	*Bulged L4-5, L5-S1	33
8.	F	*Protruded L4-5, L5-S1	41
9.	M	Protruded L4-5	57
10.	F	Bulged L5-S1	56
11.	F	*Bulged L4-5, L5-S1	21
12.	F	Protrude L4-5	57
13.	M	*Protruded L4-5, L5-S1	66
14.	F	*Bulged L4-5, L5-S1	60
15.	F	*Bulged L4-5, L5-S1	56
16.	M	Bulged L4-5	44
17.	F	*Bulged L4-5, L5-S1	48
18.	M	*Protruded L4-5, L5-S1	62

*: LDH with more than one level affected

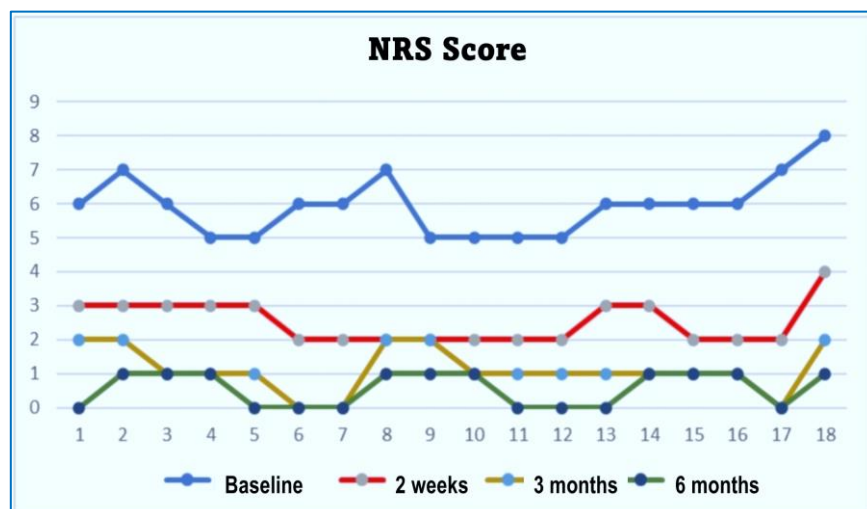


Figure 1: Pain intensity (NRS score) followed-up before and after surgery

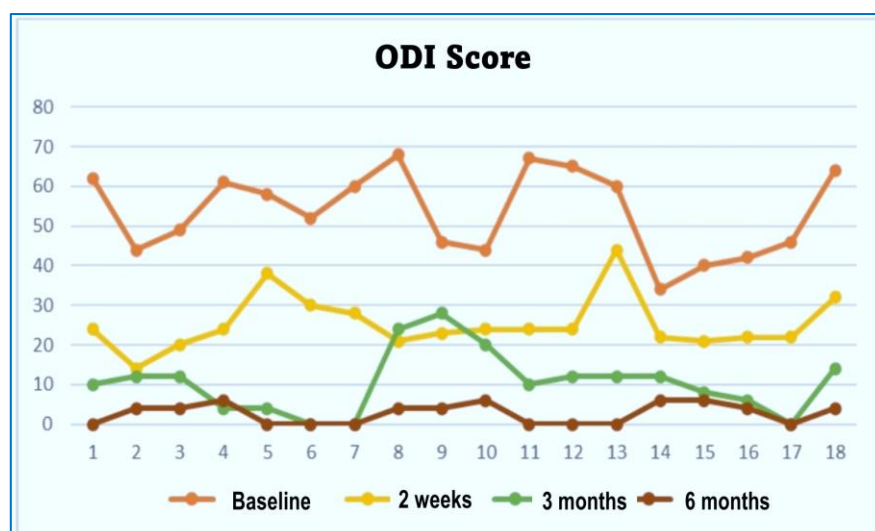


Figure 2: Activity daily living (ODI score) followed-up before and after surgery

age and the improvement in ODI scores at 2 weeks follow-up.

4. DISCUSSION

Surgery is no longer the only option for LDH, as ESI has been considered an intermediate treatment with good outcomes for LDH by about 56–65%. Systematically, this epidurolysis procedures through caudal sacral hiatus has been performed with effectiveness for managing chronic LBP than medications (Evidence level A).²¹ All subjects were without any severe complications or side effects, though they felt local injection site pain. We were concerned of the steroid related complications including the hypothalamus pituitary adrenal axis (HPA). A previous study mentioned that epidural

triamcinolone suppresses unstimulated and corticotropin releasing hormone (CRH)-stimulated adrenocorticotrophic hormone (ACTH) and cortisol secretion for 1 to 4 weeks. They monitored the urine analysis without cortisol at least 12 weeks after surgeries or more.²² Based on that we proceeded with 20 mg triamcinolone followed after epidural hyaluronidase in this study. And the study showed better improvement in epidurolysis procedures applied for managing chronic LDH, as at 2 weeks the NRS and ODI scores were improved (40–71.43%, and 23.5–68.18% respectively). Whereas a recent study applied epidural steroid injection through a foraminal approach, without satisfactory improvement of pain (27%) and ODI scores (24%).²³ Another study using caudal epidural methyl prednisolone 80 mg showed of pain improvement at 12 weeks of follow-up (83%).²⁴ Around 9.34–50% of patients have re-do surgeries in the next 3.12–3.25 weeks interval.²⁵

Our study did not find any serious complications. We used maximum volume of 17–18 mL.²⁶ Recently, a continuous epidural administrated injection @ 10 mL/h of drugs was observed not significantly to increase intracranial pressure.²⁷ We used

triamcinolone in 20 mg doses in this study due to the concerns that the higher doses (80 mg) might suppress the hypothalamus-pituitary axis. The changes might happen immediately after 15 min of injection, whereas there were no differences in outcome between low or higher dose administration.²⁸

To reach the target as the Tuohy needle tip was kept below S2 level, so the volume added might not compress the dural sac. An epidural pressure increase can lead to cerebrospinal fluid (CSF) shift into the cranium.²⁶ A single bolus injection of less than 20 mL can avoid complications, such are dural puncture headache, subdural neurotoxicity, infection, paraplegia, or hypotension due to contrast histamine release.²⁹ Triamcinolone suppressed neural discharge or inhibited C-fibers nociceptive transmission. Whereas the local

anesthetic agents lead to neural blood flow improvement. They both have thus beneficial properties in the treatment of degenerative disc herniation.³⁰

Our study showed significant improvement in pain and daily activities (Figure 3) among subjects, as followed up at 2 weeks, 3, and 6 months after surgeries. This study results were different from a previous study, which analyzed the effectiveness of CESI to improve pain or ODI scores significantly after 6 months, but 80% of the subjects needed CESI repetition.³¹ Whereas, a study of percutaneous adhesiolysis or epidurolysis by a catheter showed pain improvement at 2 weeks (61.6–70.9%), and 3 months (59.5–63.5%); and the ODI scores showed improvement at 2 weeks (70.9%) and 3 months (67.6%) respectively. Nevertheless, the study was performed by a transforaminal approach, while our study by a caudal epidural approach. As long as followed-up, the patients were asked to routinely perform 30 right-left lower trunks rotations with flexed knees while lying on the bed. In chronic cases of LDH, chronic inflammation inside the epidural space might have led to fibrosis or hypertrophic tissues within.³² Lower trunk rotation exercises are thought to help release the fibrosed tissues inside epidural space, just like neural flossing exercise which plays a role in fibrosis reduction.³³

5. LIMITATIONS

Without the use of a control group, no comparisons can be made, either with placebo or other pain management modalities. Sixth-month follow-up is classified as short-term. We did not analyze the weight, height, occupational work, or common physical exercise habits. However, further studies on a larger sample size with a control group are recommended.

6. CONCLUSION

This study proves the beneficial use of epidural hyaluronidase 1500 IU before injecting a lower dose of triamcinolone. The study offers a cost-effective method for managing bulged and chronic lumbar disc herniation with good results.

7. Data availability

The numerical data generated during this research is available with the authors.

8. Conflict of interest

The authors declare that there was no conflict of interest, and no external or industry funding was involved.

9. Acknowledgments

We thank all the colleagues working in various departments who kindly helped us and all subjects who participated in this study.

10. Authors' contribution

TB: concept, conduction of the study work and manuscript editing

AH: statistic and methodological analysis of the subjects

DT: evaluate the imaging examination that defined of LDH stages

DP: statistic and methodological analysis of the subjects

11. REFERENCES

1. Peul WC, van Houwelingen HC, van den Hout WB, Brand R, Eekhof JA, Tans JT, et al. Surgery versus prolonged conservative treatment for sciatica. *N Engl J Med*. 2007;356:2245-56. [PubMed] DOI: [10.1056/NEJMoa064039](https://doi.org/10.1056/NEJMoa064039)
2. Weinstein JN, Tosteson TD, Lurie JD, Tosteson AN, Hanscom B, Skinner JS, et al. Surgical vs nonoperative treatment for lumbar disk herniation: the Spine Patient Outcomes Research Trial (SPORT): a randomized trial. *JAMA*. 2006;296:2441-50. [PubMed] DOI: [10.1001/jama.296.20.2441](https://doi.org/10.1001/jama.296.20.2441)
3. Cosamalón-Gan I, Cosamalón-Gan T, Mattos-Piaggio G, Villar-Suárez V, García-Cosamalón J, Vega-Álvarez JA. Inflammation in the intervertebral disc herniation. *Neurocirugia (Astur : Engl Ed)*. 2021 Jan-Feb;32(1):21-35. [PubMed] DOI: [10.1016/j.neucir.2020.01.001](https://doi.org/10.1016/j.neucir.2020.01.001)
4. Fardon DF, Williams AL, Dohring EJ, Murtagh FR, Gabriel Rothman SL, Sze GK. Lumbar disc nomenclature: version 2.0: Recommendations of the combined task forces of the North American Spine Society, the American Society of Spine Radiology and the American Society of Neuroradiology. *Spine J*. 2014 Nov 1;14(11):2525-45. [PubMed] DOI: [10.1016/j.spinee.2014.04.022](https://doi.org/10.1016/j.spinee.2014.04.022)
5. Jacobsen HE, Khan AN, Levine ME, Filippi CG, Chahine NO. Severity of intervertebral disc herniation regulates cytokine and chemokine levels in patients with chronic radicular back pain. *Osteoarthritis Cartilage*. 2020 Oct;28(10):1341-1350. [PubMed] DOI: [10.1016/j.joca.2020.06.009](https://doi.org/10.1016/j.joca.2020.06.009)
6. Manchikanti L, Pampati V, Benyamin RM, Boswell MV. Analysis of efficacy differences between caudal and lumbar interlaminar epidural injections in chronic lumbar axial discogenic pain: local anesthetic alone vs. local combined with steroids. *Int J Med Sci*. 2015 Jan 20;12(3):214-22. [PubMed] DOI: [10.7150/ijms.10870](https://doi.org/10.7150/ijms.10870)
7. Ferreira-Valente MA, Pais-Ribeiro JL, Jensen MP. Validity of four pain intensity rating scales. *Pain*. 2011;152:2399-404. [PubMed] DOI: [10.1016/j.pain.2011.07.005](https://doi.org/10.1016/j.pain.2011.07.005)
8. Fairbank JC, Couper J, Davies JB, O'Brien JP. The Oswestry low back pain disability questionnaire. *Physiotherapy*. 1980 Aug;66(8):271-3. [PubMed]
9. Lee MS, Moon HS. Safety of epidural steroids: a review. *Anesth Pain Med*. 2021;16:16-27. [PubMed] DOI: [10.17085/apm.21002](https://doi.org/10.17085/apm.21002)
10. Van Boxem K, Rijsdijk M, Hans G, de Jong J, Kallewaard JW, Vissers K, et al. Safe Use of Epidural Corticosteroid Injections: Recommendations of the WIP Benelux Work Group. *Pain Pract*. 2019 Jan;19(1):61-92. [PubMed] DOI: [10.1111/papr.12709](https://doi.org/10.1111/papr.12709)
11. Manchikanti L, Knezevic NN, Sanapati MR, Boswell MV, Kaye AD, Hirsch JA. Effectiveness of Percutaneous Adhesiolysis in Managing Chronic Central Lumbar Spinal Stenosis: A

- Systematic Review and Meta-Analysis. *Pain Physician*. 2019;22:E523-E550. [PubMed]
12. Budisulistyo T, Jamilah. Clinical Outcome of Epidurolysis and Laminectomy on Lumbar Disc Herniation Treatment in Dr. Kariadi Hospital Semarang- Indonesia. 2nd International Conference of Translational Medicine and Health Sciences in Conjunction With 4th Java International Nursing Conference 2018. [Free Full Text]
 13. Ploumis A, Christodoulou P, Wood KB, Varvarousis D, Sarni JL, Beris A. Caudal vs Transforaminal Epidural Steroid Injections as Short-Term (6 Months) Pain Relief in Lumbar Spinal Stenosis Patients with Sciatica. *Pain Med*. 2014;15:379-85. [PubMed] DOI: [10.1111/pme.12318](https://doi.org/10.1111/pme.12318)
 14. Wynn TA, Vannella KM. Macrophages in Tissue Repair, Regeneration, and Fibrosis. *Immunity*. 2016 Mar 15;44(3):450-462. [PubMed] DOI: [10.1016/j.immuni.2016.02.015](https://doi.org/10.1016/j.immuni.2016.02.015)
 15. Amin RM, Andrade NS, Neuman BJ. Lumbar Disc Herniation. *Curr Rev Musculoskelet Med*. 2017 Dec;10(4):507-516. [PubMed] DOI: [10.1007/s12178-017-9441-4](https://doi.org/10.1007/s12178-017-9441-4)
 16. Borthwick LA, Wynn TA, Fisher AJ. Cytokine mediated tissue fibrosis. *Biophysica Acta*. 2013;1832(7):1049-60. [PubMed] DOI: [10.1016/j.bbadis.2012.09.014](https://doi.org/10.1016/j.bbadis.2012.09.014)
 17. Kim WH, Sim WS, Shin BS, Lee CJ, Jin HS, Lee JY, et al. Effects of Two Different Doses of Epidural Steroid on Blood Glucose Levels and Pain Control in Patients with Diabetes Mellitus. *Pain Physician* 2013;16:557-68. [PubMed]
 18. Min Soo Lee and Ho Sik Moon. Safety of epidural steroids: a review. *Anesth Pain Med*. 2021;16:16-27. [PubMed] DOI: [10.17085/apm.21002](https://doi.org/10.17085/apm.21002)
 19. Shah A, Mak D, Davies AM, James SL, Botchu R. Musculoskeletal Corticosteroid Administration: Current Concepts. *Can Assoc Radiol J*. 2019 Feb;70(1):29-36. [PubMed] DOI: [10.1016/j.carj.2018.11.002](https://doi.org/10.1016/j.carj.2018.11.002)
 20. Kozinoga M, Majchrzycki M, Piotrowska S. Low back pain in women before and after menopause. *Prz Menopauzalny*. 2015 Sep;14(3):203-7. [PubMed] DOI: [10.5114/pm.2015.54347](https://doi.org/10.5114/pm.2015.54347)
 21. Fulton A, Milanese S, Grimmer K. Systematic Review: Injection of Steroid via the Caudal Sacral Route. The International Centre for Allied Health Evidence. New Zealand, 2016. [FreeFullText]
 22. Iranmanesh A, Gullapalli D, Singh R, Veldhuis JD. Hypothalamo-Pituitary-Adrenal Axis after a Single Epidural Triamcinolone Injection. *Endocrine*. 2017;57(2):308-13. [PubMed] DOI: [10.1007/s12020-017-1357-7](https://doi.org/10.1007/s12020-017-1357-7)
 23. Ekedahl H, Jönsson B, Annertz M, Frobell RB. Three week results of transforaminal epidural steroid injection in patients with chronic unilateral low back related leg pain: The relation to MRI findings and clinical features. *J Back Musculoskelet Rehabil*. 2016 Nov 21;29(4):693-702. [PubMed] DOI: [10.3233/BMR-160671](https://doi.org/10.3233/BMR-160671)
 24. Chaudhary S, Sharma R, Kothari SY, Thukral BB. Effect of caudal epidural steroid injection in chronic low back pain due to prolapse intervertebral disc. *IJPMR*. 2015; 26(2):49-52. DOI: [10.5005/ijopmr-26-2-49](https://doi.org/10.5005/ijopmr-26-2-49)
 25. Papanna AKS, Vittaldas SR, Thirugnanam B, Srinivasa V. Epidural Steroid Injection in Herniated Disc and Lumbar Canal Stenosis: Is It Just a Placebo? *Columna*. 2021;20(3):189-91. DOI: [10.1590/S1808-185120212003241111](https://doi.org/10.1590/S1808-185120212003241111)
 26. Hilt H, Gramm HJ, Link J. Changes in intracranial pressure associated with extradural anaesthesia. *Br J Anaesth*. 1986 Jun;58(6):676-80. [PubMed] DOI: [10.1093/bja/58.6.676](https://doi.org/10.1093/bja/58.6.676)
 27. Zabolotskikh I, Trembach N. Safety and efficacy of combined epidural/general anesthesia during major abdominal surgery in patients with increased intracranial pressure: a cohort study. *BMC Anesthesiol*. 2015;15:76. [PubMed] DOI: [10.1186/s12871-015-0056-2](https://doi.org/10.1186/s12871-015-0056-2)
 28. Jung JH, Ignatius MI, Davis JM, Jim L. Long-Term Complications of Epidural Steroid Injections. *Curr Phys Med Rehabil Rep*. 2014;2:55-60. DOI: [10.1007/s40141-013-0038-6](https://doi.org/10.1007/s40141-013-0038-6)
 29. Pandey RA. Efficacy of Epidural Steroid Injection in Management of Lumbar Prolapsed Intervertebral Disc: A Comparison of Caudal, Transforaminal and Interlaminar Routes. *J Clin Diagn Res*. 2016 Jul;10(7):RC05-11. [PubMed] DOI: [10.7860/JCDR/2016/18208.8127](https://doi.org/10.7860/JCDR/2016/18208.8127)
 30. Tasdogan AM, Kilic ET. Outcome Measurements for Pain Relief in Elderly Patients with Spinal Stenosis Undergoing Epidural Steroid Injection: Is Conservative Approach an Option? *Turk Neurosurg*. 2020;30(5):734-738. [PubMed] DOI: [10.5137/1019-5149.JTN.29251-20.3](https://doi.org/10.5137/1019-5149.JTN.29251-20.3)
 31. Cervera-Irimia J, Tomé-Bermejo F. Caudal epidural steroid injection in the treatment of chronic discogenic low back pain. Comparative, prospective and randomized study. *Rev Esp Cir Ortop Traumatol*. 2013;57:324-32. [PubMed] DOI: [10.1016/j.recot.2013.05.005](https://doi.org/10.1016/j.recot.2013.05.005)
 32. Lee JH, Lee SH. Clinical Effectiveness of Percutaneous Adhesiolysis Using Navicath for the Management of Chronic Pain Due to Lumbosacral Disc Herniation. *Pain Physician*. 2012;15:213-21. [PubMed]
 33. Raczy GB, Heavner JE, Noe CE, Al-Kaisy A, Matsumoto T, Lee SC, Nagy L. Epidural Lysis of Adhesions and Percutaneous Neuroplasty. *Techniques Neurolysis*. 2016;119-143. DOI: [10.1007/978-3-319-27607-6_8](https://doi.org/10.1007/978-3-319-27607-6_8)