

CASE REPORT

INTENSIVE CARE

Management of peritoneal dialysis in an adolescent with septic shock, AKI, multi-organ failure and COVID-19: a case report

Dirgo Suseno Andiantoro^{1*}, Rudyanto Sedono², Jennefer Jennefer³

Author affiliation:

1. Dirgo Suseno Andiantoro, Intensive Care Division, Department of Anesthesiology and Intensive Therapy, Faculty of Medicine, Universitas Indonesia, Cipto Mangunkusumo Hospital, Jakarta, Indonesia; E-mail: dirgosuseno88@gmail.com; ORCID: {0000-0003-0061-0303}
2. Rudyanto Sedono, Intensive Care Division, Department of Anesthesiology and Intensive Therapy, Faculty of Medicine, Universitas Indonesia, Cipto Mangunkusumo Hospital, Jakarta, Indonesia; E-mail: rudyanto_sedono@yahoo.com
3. Jennefer Jennefer, Intensive Care Division, Department of Anesthesiology and Intensive Therapy, Faculty of Medicine, Universitas Indonesia, Cipto Mangunkusumo Hospital, Jakarta, Indonesia; E-mail: jenneferlim13@gmail.com; ORCID: {0000-0003-1425-8427}

Correspondence: Dirgo Suseno Andiantoro, E-mail: dirgosuseno88@gmail.com; Telephone: 021-314 3736 / 314 8865 / 3912526; Fax: 021-3912526

ABSTRACT

The kidneys is the most commonly injured organs in sepsis, which might manifest as acute kidney injury (AKI). Peritoneal dialysis (PD) is the preferred modality of renal replacement therapy (RRT), especially in the developing countries. Furthermore, the COVID-19 pandemic has made hemodialysis (HD) unavailable due to infection concerns. We present a critically-ill 16-year-old male with morbid obesity (BMI 43.3 kg/m²), diabetic ketoacidosis, acute pancreatitis, acute kidney injury, and COVID-19 pneumonia. The patient looked somnolent on admission with very high random blood glucose and hypernatremia. Blood gas analysis showed metabolic acidosis. The patient was treated with 1 g/day Meropenem, 0.5 µg/kg/min norepinephrine, 0.04 unit/kg/h vasopressin, and correction of electrolyte imbalance and metabolic acidosis. After 48 h, the diuresis and the creatinine levels worsened. We placed a Tenckhoff catheter and started PD. The patient showed improvement after 72 h of peritoneal dialysis.

This case report highlighted the use of PD as a modality of RRT in sepsis-induced AKI, multi-organ failure, and COVID-19. Although it remains controversial, we observed an improvement in diuresis and creatinine levels following PD. PD is more cost-effective and provides a similar outcome compared to other modalities.

Abbreviations: AKI - Acute Kidney Injury; BMI- Body Mass Index; CRRT- Continous Renal Replacement Therapu; GCS- Glasgow Coma Scale; HD- Hemodialysis; ICU- Intensive Care Unit; PD- Peritoenal Dialysis; RRT- Renal Replacement Therapy; S-AKI- Sepsis-Associated Acute Kidney Injury; SIRS- Systemic Inflammatory Response Syndrome

Key words: Septic shock; Acute kidney injury; Peritoneal dialysis

Citation: Andiantoro DS, Sedono R, Jennefer J. Management of peritoneal dialysis in an adolescent with septic shock, AKI, multi-organ failure and COVID-19: a case report. *Anaesth. pain intensive care* 2023;27(4):600–603.

DOI: [10.35975/apic.v27i4.2163](https://doi.org/10.35975/apic.v27i4.2163)

Received: February 14, 2023; **Reviewed:** April 17, 2023; **Accepted:** April 22, 2023

1. INTRODUCTION

Sepsis is the leading cause of acute kidney injury (AKI). The most frequent source of infection that causes sepsis is the respiratory tract, including COVID-19 pneumonia.¹ Kidney hypoperfusion, hemodynamic instability, inflammatory mediators, and kidney vascular

dysfunction and inflammation result in acute tubular necrosis, ischemia-reperfusion damage to the glomeruli, inflammation of the nephrons, oxidative stress, renal tubular injury, and apoptosis of the tubular and renal mesenchyme. These conditions are known to cause sepsis-induced AKI.²⁻⁴ Lack of perfusion manifests as lactic acidosis, oliguria, or alteration in the mental status.¹

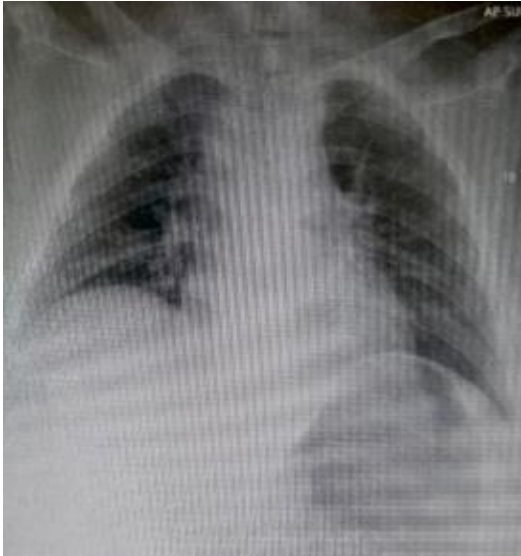

Figure 1: Chest X-ray shows increased bronchovascular markings and opacities in the lung fields.

The treatment of AKI is renal replacement therapy (RRT), with either continuous RRT, hemodialysis (HD), or peritoneal dialysis (PD), with the latter being an option for kidney failure. The geographic location, socio-economic conditions, and clinical manifestations of the patient appear to affect the selection of the modality.⁵ PD is sometimes the primary dialysis choice in low- to middle-income countries. It can remove waste products from the body using dialysate and the peritoneum as a filter for this process.⁴ This case report highlights the use of PD as a treatment modality for sepsis-associated acute kidney injury (S-AKI) in an adolescent with multi-organ failure. The objective is to remind the physicians treating sepsis-induced renal failure about the usefulness of PD when other options are restricted or non-available.

2. CASE REPORT

A 16-year-old male presented to the emergency department with sudden loss of consciousness. Glasgow Coma Scale (GCS) was 8 for the last 5 h prior to hospitalization, and this SARS CoV-2 test was positive. His body temperature was 39.8°C, heart rate 144 beats/min, respiratory rate 30 breaths/min, blood pressure 83/52 mmHg, and oxygen saturation at 97% with 4 L/min oxygen administered via a nasal cannula. Physical examination revealed him to be obese with BMI 43.3 kg/m², and rales at the basal areas of the lungs. Laboratory results were remarkable for undetectable very high blood glucose level, hypernatremia (serum sodium 156 mmol/L), hyperchloremia (120 mEq/L), and elevated lactate level (2.8 mmol/L). His blood gas analysis revealed pH 6.9, PCO₂ 23.4 mmHg, PaO₂ 122 mmHg, HCO₃⁻ 10 meq/L, an elevated creatinine 2.3

mg/dl and procalcitonin 12 ng/ml. Amylase was 566 U/L, and lipase was 128 U/L. The patient presented with hypotension unresponsive to fluid resuscitation. The patient was intubated and ventilated, a chest X-ray obtained (Figure 1) and transferred to the intensive care unit (ICU).

The patient was diagnosed with septic shock and sepsis induced AKI based on the clinical and laboratory findings. The patient's condition was accompanied by morbid COVID-19 pneumonia, diabetic ketoacidosis, acute pancreatitis, and obesity.

The ventilator setting were: AC/PC mode with FiO₂ 35%, P_{ins} 12 cmH₂O, PEEP 5 cmH₂O, RR 15/min, and PS 12 cmH₂O. Norepinephrine infusion was started to maintain adequate blood pressure, followed by vasopressin infusion. After normalizing the acidemia and electrolyte imbalances, vasopressors could be tapered off. The patient was started on meropenem, ciprofloxacin, and remdesivir while sedated with ketamine 40 µg/kg/h. By the second day of hospitalization, a net positive fluid balance of 2.5 L was noted, and the hypernatremia persisted (serum sodium of 153 mmol/L). We started furosemide infusion 5 mg/h. After 3 h of furosemide, the patient's urine output remained at only 0.2 ml/kg, and the creatinine level rose to 7.62 mg/dl. We placed Tenckhoff catheter in the rectovesical pouch and PD was started for the next 72 h, with dialysate solution containing insulin, potassium, heparin, and ceftazidime.

After 72 h of PD, the patient showed an improvement in diuresis of 0.7 ml/kg/h. His creatinine level dropped to 6.12 mg/dl and 5.13 mg/dl the subsequent day. He remained hospitalized in the ICU for nine days.

3. DISCUSSION

The sepsis-induced AKI in our patient may have multifactorial causes, such as COVID-19 pneumonia, diabetic ketoacidosis, acute pancreatitis, and obesity. Diabetic ketoacidosis is associated with acute pancreatitis, which can lead to beta-cell dysfunction and transient insulin deficiency and increase insulin resistance due to systemic inflammation. Patients with diabetic ketoacidosis are at greater risk of developing systemic inflammatory response syndrome (SIRS).⁶

he patient was obese class-III, with a BMI of 43.3 kg/m². Research conducted by Ganda et al. found that the prevalence of S-AKI patients with malnutrition was higher than patients with normal nutritional states. Malnutrition affects systemic function, including immunity, cell damage, and membrane permeability of the intestinal mucosa, which promotes bacterial translocation. This condition increases the risk of pneumonia, sepsis, and other infections, resulting in

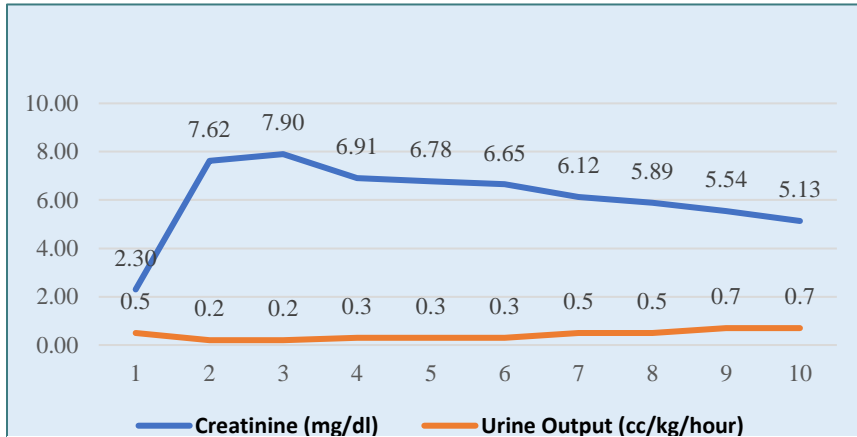


Figure 2: A line graph of the patient’s serum creatinine and urine output from his admission to day 10. The patient’s serum creatinine and urine output showed improvement after 72 h of PD.

will remain in the peritoneum for 40 min to one hour and be exchanged every 6 h. The procedure of PD is technically straightforward, does not require vascular access or expensive equipment, and is more practical and safer as an RRT.⁸ Additionally, it can be performed with or without a machine. + PD with peel-away Tenckhoff catheters have a substantially reduced risk of complication than CRRT.^{4,9}

A prospective study showed that early PD therapy in patients with S-AKI was correlated with early renal improvement while also

higher mortality, increased length of hospitalization and care cost.¹

RRT modalities for pediatric AKI have evolved from PD, HD, continuous renal replacement therapy (CRRT), to sustained low-efficiency dialysis (SLED).⁷ The socio-economic and clinical characteristics of the patient are factors that influence the choice of treatment with PD. Several retrospective cohort studies have shown that PD can be conducted in pediatric patients with hemodynamic instability and multi-organ failure requiring vasopressors,⁵ as in our patient and the PD therapy we used.

We used a dialysate with a combination of 2 L of 2.5% dextrose with 1000 U heparin, 10 mEq potassium, 10 U Novorapid®, and 250 mg ceftazidime. In PD, the peritoneum functions as a filter and the dialysate solution

being associated with decreased PD duration, early dialysis termination, and fewer procedural risks.⁴ PD does not require extracorporeal circulation and does not involve blood exposure to synthetic membranes, so the hemodynamic tolerance is relatively good. These factors potentially contribute to the early recovery of kidney function.¹⁰ Our patient showed an improvement in diuresis of 0.7 ml/kg/h, and a fall in creatinine level to 5.5 mg/dl.

Prior to the COVID-19 pandemic, CRRT was the first choice for RRT in S-AKI, especially in hemodynamically unstable patients. However, after the pandemic, numerous hospitals found it difficult to allocate HD machines for many COVID-19 with AKI due to cross-infection risks.⁹

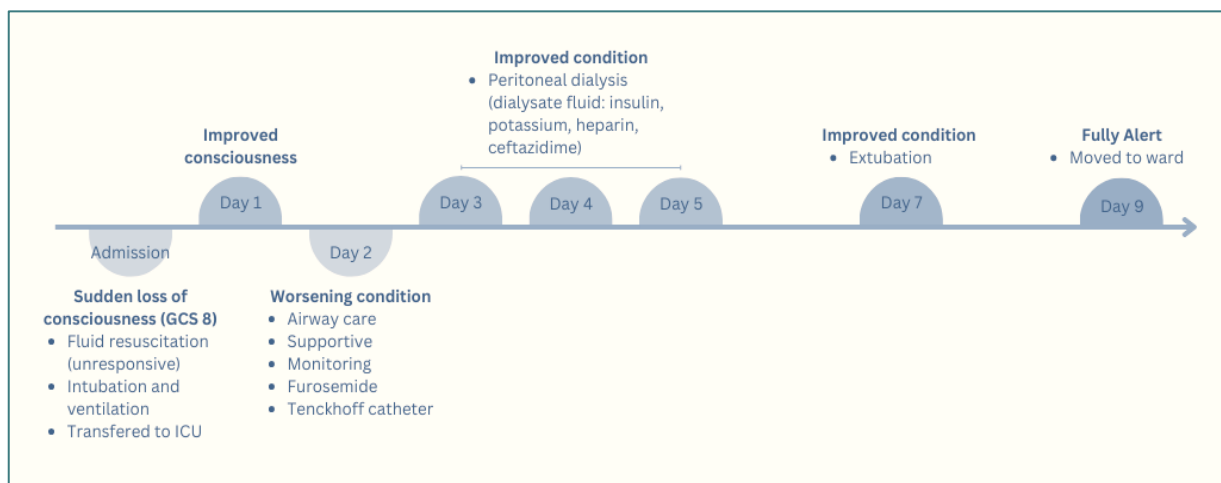


Figure 3: Patient’s condition timeline. The patient came with a sudden loss of consciousness and presented unresponsive hypotension to fluid resuscitation, then the patient was moved to ICU. The peritoneal dialysis was started on day 3 for the next 72 h,

Some concerns regarding PD have been raised, including whether appropriate clearance and ultrafiltration can be accomplished, and the peritonitis risk and the impact of protein loss and glucose absorption. These factors lead to PD being practiced only in developing countries where advanced therapies are still minimal. However, recent data showed that mortality and complication rates of PD in AKI have decreased even further and there is no reason to believe that other modalities offer any advantage over PD in regards to the outcome.¹⁰

4. CONCLUSION

Peritoneal dialysis can be one of the treatment options for AKI, especially in patients with sepsis, in countries where advanced therapies are not readily available. It is cost-effective, can easily be performed, and does not require vascular access and expensive equipment. It offers outcomes comparable to hemodialysis. This therapy needs to be evaluated further to weigh its risks and outcomes.

5. Ethical committee approval

Ethical approval is not required for this study in accordance with local or national guidelines.

6. Consent to participate

Written informed consent for publication was obtained from the patient's biological father for publication of this case report with any accompanying images.

7. Availability of Data and Materials

Numerical data is available from the authors upon reasonable request and with permission of the hospital administration.

8. Conflict Interests

The authors declare that they have no conflicting interests.

9. Acknowledgments

This article was presented at the 7th International Conference and Exhibition on Indonesian Medical Education and Research Institute (7th ICE on IMERI), Faculty of Medicine, Universitas Indonesia. We appreciate the exceptional support of the 7th ICE on the IMERI committee during the manuscript preparation and peer-review process.

10. Author's Contributions

Conceptualization: RS. Writing-original draft: DSA. Writing-review & editing: DSA, JJ. All authors read and approved the final manuscript.

11. REFERENCES

- Ganda IJ, Karjana, Daud D. Association between sepsis induced acute kidney injury with shock and length of stay in critically ill pediatric patients. *Curr Pediatr Res.* 2019;23(2):64–70. [FreeFullText]
- Alexander MP, Mangalaparthy KK, Madugundu AK, Moyer AM, Adam BA, Mengel M, et al. Acute kidney injury in severe COVID-19 has similarities to sepsis-associated kidney injury: a multi-omics study. *Mayo Clin Proc.* 2021;96(10):2561–75. [PubMed] DOI: [10.1016/j.mayocp.2021.07.001](https://doi.org/10.1016/j.mayocp.2021.07.001)
- Leghrouz B, Kaddourah A. Impact of acute kidney injury on critically ill children and neonates. *Front Pediatr.* 2021;9:635631. [PubMed] DOI: [10.3389/fped.2021.635631](https://doi.org/10.3389/fped.2021.635631)
- Tomar A, Kumar V, Saha A. Peritoneal dialysis in children with sepsis-associated AKI (SA-AKI): an experience in a low- to middle-income country. *Paediatr Int Child Health.* 2021;41(2):137–44. [PubMed] DOI: [10.1080/20469047.2021.1874201](https://doi.org/10.1080/20469047.2021.1874201)
- Nourse P, Cullis B, Finkelstein F, Numanoglu A, Warady B, Antwi S, et al. ISPD guidelines for peritoneal dialysis in acute kidney injury: 2020 update (paediatrics). *Perit Dial Int.* 2021;41(2):139–57. [PubMed] DOI: [10.1177/0896860820982120](https://doi.org/10.1177/0896860820982120)
- Bouchaala K, Bahloul M, Bradii S, Kallel H, Chtara K, Bouaziz M. Acute pancreatitis induced by diabetic ketoacidosis with major hypertriglyceridemia: report of four cases. *Case Rep Crit Care.* 2020;2020:7653730. [PubMed] DOI: [10.1155/2020/7653730](https://doi.org/10.1155/2020/7653730)
- Sethi SK, Bunchman T, Chakraborty R, Raina R. Pediatric acute kidney injury: new advances in the last decade. *Kidney Res Clin Pract.* 2021;41(1):40–51. [PubMed] DOI: [10.23876/j.krcp.20.074](https://doi.org/10.23876/j.krcp.20.074)
- Vigiola Cruz M, Bellorin O, Srivatana V, Afaneh C. Safety and efficacy of bedside peritoneal dialysis catheter placement in the COVID-19 era: initial experience at a New York City hospital. *World J Surg.* 2020;44(8):2464–70. [PubMed] DOI: [10.1007/s00268-020-05600-4](https://doi.org/10.1007/s00268-020-05600-4)
- Shemies RS, Nagy E, Younis D, Sheashaa H. Renal replacement therapy for critically ill patients with COVID-19-associated acute kidney injury: a review of current knowledge. *Ther Apher Dial.* 2022;26(1):15–23. [PubMed] DOI: [10.1111/1744-9987.13723](https://doi.org/10.1111/1744-9987.13723)
- Ponce D, Gobo-Oliveira M, Balbi AL. Peritoneal dialysis treatment modality option in acute kidney injury. *Blood Purif.* 2017;43(1–3):173–8. [PubMed] DOI: [10.1159/000452703](https://doi.org/10.1159/000452703)