

CASE REPORT

INTENSIVE CARE

Severe lymphopenia as an early marker for immunoparalysis in massive ischemic stroke: a case report

Berri Primayana¹, Adhrie Sugiarto¹, Vera Irawany²

Author affiliation:

1. Berri Primayana, Trainee of Intensive Care Fellowship Program, Department of Anesthesiology & Intensive Care, Faculty of Medicine Universitas Indonesia - Cipto Mangunkusumo National General Hospital, Jakarta Pusat 10430, Indonesia; ORCID: {0000-0002-6470-6286} E-mail: primayanaberri@gmail.com
2. Adhrie Sugiarto, Intensive Care Consultant, Department of Anesthesiology & Intensive Care, Faculty of Medicine Universitas Indonesia - Cipto Mangunkusumo National General Hospital, Jakarta Pusat 10430, Indonesia; ORCID: {0000-0003-2542-1373} E-mail: adhrie@gmail.com
3. Vera Irawany, Intensive Care Consultant, Department of Anesthesiology & Intensive Care, Fatmawati General Hospital, Cilandak Barat, Jakarta Selatan, 12430, Indonesia; ORCID: {0000-0001-5081-7498} E-mail: bundavea@gmail.com

Correspondence: Berri Primayana; Tel: +6281363245131; E-mail: primayanaberri@gmail.com

ABSTRACT

A 72-year-old female presented to the emergency room (ER) of Fatmawati Hospital with pneumonia and ketosis. After 12 h, her level of consciousness (LoC) decreased and she developed shortness of breath. In the ICU, antibiotics and supportive therapies were administered. After several hours, the need for vasopressors increased. Laboratory results showed severe lymphopenia, increased neutrophil to lymphocyte ratio (NLR) and D-Dimer levels. Septic shock and decreased LoC with severe immunoparalysis can be caused by intracranial process. A brain CT scan revealed massive ischemic stroke. Measures were taken to reduce intracranial pressure. Continuous Renal Replacement Therapy (CRRT) was performed for blood purification and immunomodulation. Vasopressor requirements decreased, her absolute lymphocyte increased and her NLR decreased. Diuresis and fluid balance were improved. She was subsequently discharged to the ICU. In this patient, massive ischemic stroke induced immunoparalysis, which manifested as lymphopenia and increased susceptibility to infection. Severe lymphopenia can be used as an early marker of ischemic stroke with signs of sepsis.

Abbreviations: CRRT - Continuous Renal Replacement Therapy; ER – Emergency Room; IFN- γ - Interferon-gamma; LoC - Level of consciousness; NLR - Neutrophil to lymphocyte ratio; SIIS - stroke-induced immunosuppression; TNF- α - Tumor Necrosis Factor- α

Key words: CRRT; Immunoparalysis; Immunomodulation; Lymphopenia; Massive Ischemic Stroke

Citation: Primayana B, Sugiarto A, Irawany V. Severe lymphopenia as an early marker for immunoparalysis in massive ischemic stroke: a case report. *Anaesth. pain intensive care* 2023;27(2):272–275; DOI: [10.35975/apic.v27i2.2139](https://doi.org/10.35975/apic.v27i2.2139)

Received: January 23, 2023; **Reviewed:** January 30, 2023; **Accepted:** March 10, 2023

1. INTRODUCTION

Ischemic stroke is a leading cause of disability which affects the nervous and immune systems. Massive ischemia induces inflammatory responses in the brain and lymphoid organs that persist for less than 24 h and decrease significantly thereafter; therefore, putting the patients in immunoparalysis. This is a compensatory mechanism known as stroke-induced

immunosuppression (SIIS), a condition which protects the body from lethal inflammatory responses, but also makes the body more susceptible to infections, including pneumonia that could progress to sepsis. Markers of SIIS include lymphopenia, splenic atrophy and elevated anti-inflammatory cytokines. Immunosuppression can also be explained by the brain-gut axis theory. Stroke can reduce the diversity of gut microbiota species (dysbiosis). This case report illustrates an

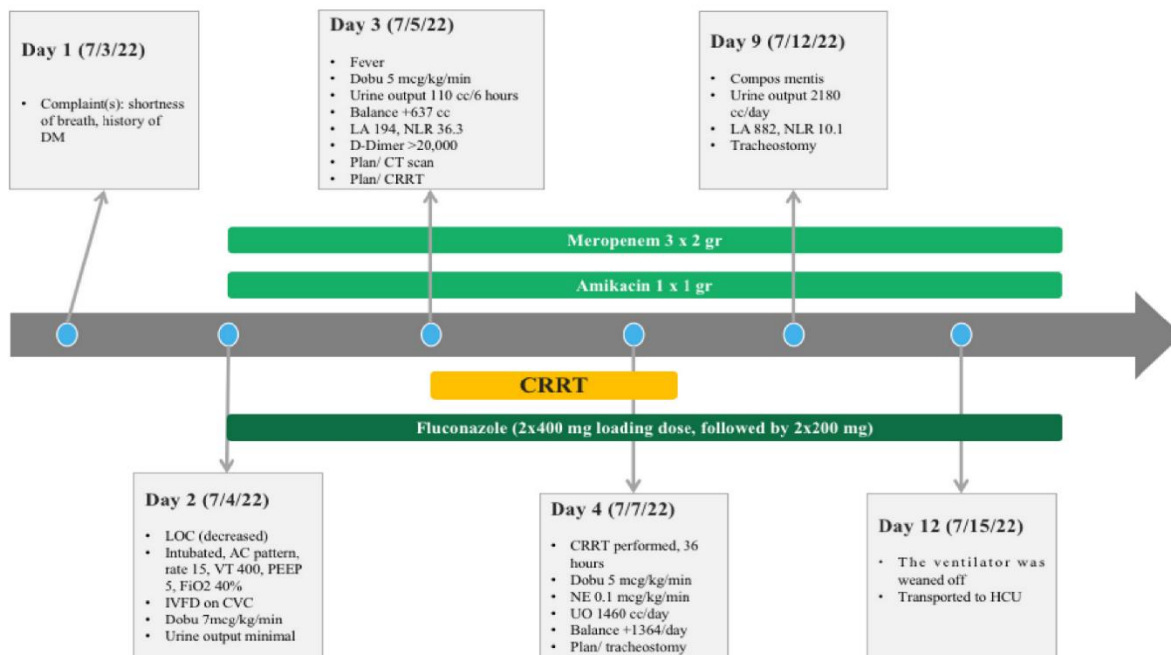


Figure 1: Patient’s timeline showing management and her day to day progress

immunoparalysis in a patient with massive ischemic stroke.1-3

2. CASE REPORT

A 72-year-old female presented to the ER of Fatmawati Hospital fully conscious with shortness of breath and history of diabetes mellitus. She was initially diagnosed with pneumonia and ketosis. Several hours later, her level of consciousness (LoC) dropped to 7 (E2V2M3) on the Glasgow Coma Scale, with worsening shortness of breath. She was then classified as a red category patient according to the hospital triage protocol, was intubated and had a CVC inserted and subsequently admitted to the

ICU. She was treated with antibiotics and supportive therapy in the ICU.

After several hours the patient’s need for vasopressors increased and her laboratory results showed severe lymphopenia, increased neutrophil to lymphocyte ratio (NLR) and D-Dimer levels. Septic shock and decrease of consciousness with severe immunoparalysis could be caused by an intracranial process. A brain CT scan was performed, revealing a massive ischemic stroke.

In the ICU, the patient’s absolute lymphocyte count dropped to 194/ μ L. Her NLR increased from 15.3 to 36.3, and the D-Dimer and PCT levels went up to >20,000 mg/L and 3.74 ng/mL, respectively. The patient

was diagnosed with septic shock and suspected SIRS. CT scan was performed (Figure 2-A) and a massive infarction was detected. Her chest X-ray showed pneumonic infiltrates on the second day (Figure 2-B)

She was put on antibiotic regimens consisting of

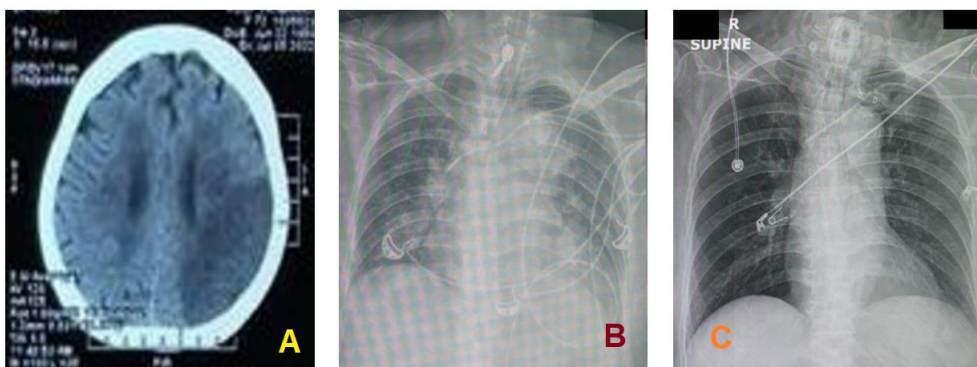


Figure 2 (A): CT scan showing massive Infarction. (B) Chest X-ray showing pneumonic infiltrates on the second day (C) Chest X-ray showing lung by the tenth day

meropenem 2 g every 8 h, amikacin 1 g daily and fluconazole 800 mg as initial dose, followed by 200 mg every 12 h. However, the need for vasopressors increased and she clinically deteriorated. On the third day, Continuous Renal Replacement Therapy (CRRT) was performed for 36 h.

During CRRT, her condition improved. She could open her eyes and gave minimal response to verbal stimulation. On the seventh day, her absolute lymphocyte count increased, NLR and D-Dimer level decreased. Her renal function improved, urine output increased and serum creatinine decreased. After 10 days, a chest X-ray was ordered, which now looked normal with no consolidation or infiltrates (Figure 2-C).

The patient regained complete consciousness, her fever subsided and vasopressor use was discontinued. After tracheostomy on the ninth day, the patient was weaned off the ventilator. She was moved to a high dependency unit (HDU) on the twelfth day.

3. DISCUSSION

The immune and nervous systems are interconnected to maintain homeostasis.^{2,4} Stroke causes inflammatory and immune responses in the brain and immune organs, leading to activation and infiltration of inflammatory cells into the brain.^{4,5} Increased peripheral vascular leukocytes seen during the first 72 h after onset leads to the worsening of cerebral ischemia.⁶ Our patient was initially diagnosed with pneumonia and ketosis. Within a few hours her condition deteriorated. She was admitted to the ICU. Her diabetes mellitus was controlled with insulin. She was put on antibiotics. However, her need for vasopressors increased and she clinically deteriorated. Her absolute lymphocyte count decreased from 561 to 194/ μ L, and her NLR increased from 15.3 to 36.7. Her D-Dimer level was > 20,000 mg/L. Septic shock and decreased level of consciousness followed by severe immunoparalysis can be suspected as SIIS, which can last for several hours to several days.⁷ Brain CT scan confirmed that there was an extensive left temporoparietal infarct, cytotoxic edema phase on the right thalamic region, multiple lacunar infarcts on the left thalamic region and right basal ganglia. In ischemic stroke, there is an increase in cytokines, chemokines, and pro-inflammatory mediators in the first 24 h due to reperfusion damage, followed by an increase in anti-inflammatory mediators. Immunoparalysis in ischemic stroke tends to be more severe than in hemorrhagic stroke. Reperfusion trauma and nerve cell death in ischemic stroke are closely related to the migration of neutrophils to the brain parenchyma and the release of various proteases.⁸ Brain injury induces activation of neurogenic pathways, such as the sympathetic nervous system and hypothalamic-pituitary-adrenal axis, which

work together to influence the magnitude and intensity of systemic immune response.^{2,4} During the first few hours after onset, immunosuppression occurs.⁴ One of the main processes of SIIS is the shift of Type-1 T helper cells (Th1) to Type-2 T helper cells (Th2) response, which is characterized by the secretion of pro-inflammatory cytokines such as Tumor Necrosis Factor- α (TNF- α) and Interferon-gamma (IFN- γ), promoting the anti-inflammatory response of Th2, with the secretion of interleukin-10 receptor (IL-10) and interleukin-4 receptor (IL-4). This further leads to lymphocytopenia and decrease of Th1/Th2 ratio.⁹ Stroke changes immune activity in the gut due to two-way communication between the intestines and the brain, which is referred to the brain-gut microbiota axis. In this patient, pneumonia could be caused by dysbiosis due to stroke. Stroke causes damage to the intestinal mucosa and changes the composition of the microbiota; it also increases the risk of translocation of selective bacterial strains from the gut microbiota to peripheral tissues both both via blood and lymphatic routes, thereby inducing post-stroke infection.¹⁰ An increase in plasma anti-inflammatory cytokines in septic shock patients leads to poor prognosis. To reduce the effect and the number of circulating cytokines, CRRT was performed on the third day with the purpose of blood purification and immunomodulation. CRRT plays an important role in lowering the inflammatory response by eliminating non-selective cytokines to restore hemodynamic stability and homeostasis of the immune system.^{11,12} This was proven by the increasing absolute lymphocyte count and the decreasing NLR as signs of improvement from immunoparalysis. Clinical data showed that the patient's hemodynamic parameters improved even as vasopressor support was discontinued. Another positive effect was the improvement of kidney function with an increase in urine production and a decrease in serum creatinine level after CRRT was performed. On the ninth day, the immunoparalysis had improved and tracheostomy was performed to protect the airway and speed up the ventilator weaning process to prevent the occurrence of VAP. The next day, the patient was weaned off the ventilator. On the twelfth day, she was discharged to the HDU.

4. CONCLUSION

Immunoparalysis, which is characterized by severe lymphopenia, altered mental status, and decreased NLR in septic patients could occur due to the presence of an intracranial process. Immunoparalysis in ischemic stroke is usually more severe than in hemorrhagic stroke. LA and NLR can be used as markers for SIIS, as they are accessible and affordable. Prompt and precise suspicion leads to better clinical judgment. Early and appropriate

intervention and management will also improve patient outcomes and reduce the ICU length of stay.

5. Acknowledgment

The patient thanked contributing medical personnel who had given their full attention to help her recover. She found that the right, quick and sincere treatment had helped her pull through the critical condition. She was grateful that she could be discharged from the ICU and also wished all the health to the medical personnel.

This article was presented in the 7th International Conference and Exhibition on Indonesian Medical Education and Research Institute (7th ICE on IMERI), Faculty of Medicine, Universitas Indonesia. We appreciate the exceptional support of the 7th ICE on IMERI committee during manuscript preparation and peer-review process.

6. Conflict of interest

No potential conflict of interest relevant to this article was reported.

7. Funding

No funding, whether institutional or industry, was involved in this study.

8. Author's contribution

BP: Conceptualization; data curation; formal analysis; project administration; writing - original draft; writing - review & editing.

AS,VI: Writing - original draft; writing - review & editing.

9. REFERENCES

1. Dirnagl U, Klehmet J, Braun JS, Harms H, Meisel C, Ziemssen T, et al. Stroke-induced immunodepression. *Stroke*. 2007 Feb;38(2 Suppl):770-773. [PubMed] DOI: [10.1161/01.STR.0000251441.89665.bc](https://doi.org/10.1161/01.STR.0000251441.89665.bc)
2. Malone K, Amu S, Moore AC, Waeber C. The immune system and stroke: from current targets to future therapy. *Immunol Cell Biol*. 2019;97:5-16. [PubMed] DOI: [10.1111/imcb.12191](https://doi.org/10.1111/imcb.12191)
3. Monneret G. How to identify systemic sepsis-induced immunoparalysis. *Advances in Sepsis*. 2005;4(2):42-49. [Internet] Accessed on May 28, 2022
4. Dantzer R. Neuroimmune interactions: from the brain to the immune system and vice versa. *Physiol Rev*. 2018;98(1):477-504. [PubMed] PMID: [PMC5866360](https://pubmed.ncbi.nlm.nih.gov/300392016/) DOI: [10.1152/physrev.00039.2016](https://doi.org/10.1152/physrev.00039.2016)
5. Rayasam A, Hsu M, Kijak JA, Kissel L, Hernandez G, Sandor M, Fabry Z. Immune responses in stroke: how the immune system contributes to damage and healing after stroke and how this knowledge could be translated to better cures? *Immunology*. 2018 Jul;154(3):363-376. [PubMed] PMID: [PMC6002204](https://pubmed.ncbi.nlm.nih.gov/3002204/) DOI: [10.1111/imm.12918](https://doi.org/10.1111/imm.12918)
6. Juli C, Heryaman H, Nazir A, Ang ET, Defi IR, Gamayani U, et al. The lymphocyte depletion in patients with acute ischemic stroke associated with poor neurologic outcome. *Int J Gen Med* 2021;14:1843-1851. [PubMed] PMID: [PMC8131088](https://pubmed.ncbi.nlm.nih.gov/308325/) DOI: [10.2147/IJGM.S308325](https://doi.org/10.2147/IJGM.S308325)
7. Mahapatra S, Heffner AC. Septic shock. In: *StatPearls* [Internet]. Treasure Island (FL): StatPearls Publishing; 2022. Available from: www.ncbi.nlm.nih.gov/books/NBK430939/
8. Enzmann G, Kargaran S, Engelhardt B. Ischemia-reperfusion injury in stroke: impact of the brain barriers and brain immune privilege on neutrophil function. *Ther Adv Neurol Disord* 2018;11:1756286418794184. [PubMed] PMID: [PMC6111395](https://pubmed.ncbi.nlm.nih.gov/30611395/) DOI: [10.1177/1756286418794184](https://doi.org/10.1177/1756286418794184)
9. Theodorou GL, Marousi S, Ellul J, Mougiou A, Theodori E, Mouzaki A, et al. T helper 1 (Th1)/Th2 cytokine expression shift of peripheral blood CD4+ and CD8+ T cells in patients at the post-acute phase of stroke. *Clin Exp Immunol*. 2008 Jun;152(3):456-63. [PubMed] PMID: [PMC2453204](https://pubmed.ncbi.nlm.nih.gov/303204/) DOI: [10.1111/j.1365-2249.2008.03650.x](https://doi.org/10.1111/j.1365-2249.2008.03650.x)
10. Carabotti M, Scirocco A, Maselli MA, Severi C. The gut-brain axis: interactions between enteric microbiota, central and enteric nervous systems. *Ann Gastroenterol*. 2015;28(2):203-209. [PubMed] PMID: [PMC4367209](https://pubmed.ncbi.nlm.nih.gov/3067209/)
11. Chaudhry H, Zhou J, Zhong Y, Ali MM, McGuire F, Nagarkatti PS, et al. Role of cytokines as a double-edged sword in sepsis. *In Vivo*. 2013;27(6):669-84. [PubMed] PMID: [PMC4378830](https://pubmed.ncbi.nlm.nih.gov/304378830/)
12. Monard C, Rimmelé T, Ronco C. Extracorporeal blood purification therapies for sepsis. *Blood Purif*. 2019;47 Suppl 3:1-14. [PubMed] DOI: [10.1159/000499520](https://doi.org/10.1159/000499520)