

CASE REPORT

INTENSIVE CARE

Uncontrolled diabetic ketoacidosis can lead to brain stem infarct and death; a case report

Nur Jihan Mohd Zukhi, Mohd Zulfakar Mazlan, Fatanah Mohamad Suhaimi

Author affiliations:

1. Nur Jihan Mohd Zukhi, Universiti Sains Malaysia, 11800 Gelugor, Penang, Malaysia; E-mail: jihanzukhi@gmail.com
2. Mohd Zulfakar Mazlan, {ORCID:0000-0002-3452-1280}, Department of Anesthesiology and Intensive Care, School of Medical Science, Universiti Sains Malaysia, Kubang Kerian, 15200 Kota Bharu, Kelantan, Malaysia; E-mail: zulfakar@usm.my
3. Fatanah Mohamad Suhaimi, Universiti Sains Malaysia, 11800 Gelugor, Penang, Malaysia; E-mail: fatanah.suhaimi@usm.my

Correspondence: Mohd Zulfakar Mazlan; E-mail: zulfakar@usm.my; Phone: 097676104; Mobile: 60 0129091447

Abstract

Diabetic ketoacidosis (DKA) is a triad of hyperglycemia, metabolic acidosis and ketosis. It is a life-threatening complication of diabetes mellitus (DM) that can lead to death without appropriate treatment. DKA with stroke increases morbidity and mortality in the intensive care unit (ICU). A 37-year-old male was brought to the emergency department with sudden onset of weakness for the past two days. He had been diagnosed with type 2 DM five years earlier, but it was poorly controlled. On examination, his Glasgow Coma Scale was within normal limits. Laboratory and radiological investigations revealed severe hyperglycemia, metabolic acidosis, and brain stem infarct. He required intubation and was admitted to the ICU with a diagnosis of DKA and cerebellar and brain stem infarct. The patient succumbed to death despite 13 days of ICU management. DKA can precipitate a cerebellar and brain stem infarct, but it can be fatal despite extreme management in the ICU.

Abbreviations: DKA - Diabetic ketoacidosis; DM - Diabetes mellitus; ICU - Intensive care unit; CED - Cerebral edema; ED - Emergency department

Key words: Diabetic ketoacidosis; Stroke; Brain stem infarct; Cerebral edema; Mortality

Citation: Zukhi NJM, Mazlan MZ, Suhaimi FM. Uncontrolled diabetic ketoacidosis can lead to brain stem infarct and death; a case report. *Anaesth. pain intensive care* 2022;26(2):253–256; DOI: [10.35975/apic.v26i2.1808](https://doi.org/10.35975/apic.v26i2.1808)

Received: December 24, 2021; **Reviewed:** February 07, 2022; **Accepted:** February 07, 2022

1. Introduction

Diabetic ketoacidosis (DKA) is a state of insulin deficiency or abnormal insulin. Acute inflammatory episodes of infection, stress and non-compliance with diabetes mellitus (DM) treatment are commonly believed to be triggering factors for DKA. DKA is one of the most life-threatening endocrine disorders. It commonly occurs in type 1 DM; however, patients with type 2 DM are vulnerable to DKA.¹

Severe dehydration and acidosis at the time of DKA presentation are risks for cerebral edema (CED). CED can occur after several hours of intravenous fluid with insulin. CED is a well-known complication of major ischemic strokes, and severe CED can lead to death. CED

occurs because of cerebral capillary endothelial dysfunction and, ultimately, the breakdown of the blood-brain barrier. DKA and stroke with CED are not easy to manage if they occur simultaneously. The balance between the risk of CED and dehydration is of utmost importance in management. One study determined that the mortality rate related to CED was 24%.² The diagnosis of CED should be prioritized to prevent central nervous system complications of DKA. Failure to detect CED early in the context of aggressive fluid rehydration to correct DKA can lead to worsening CED and cardiac arrest.

2. Case Report

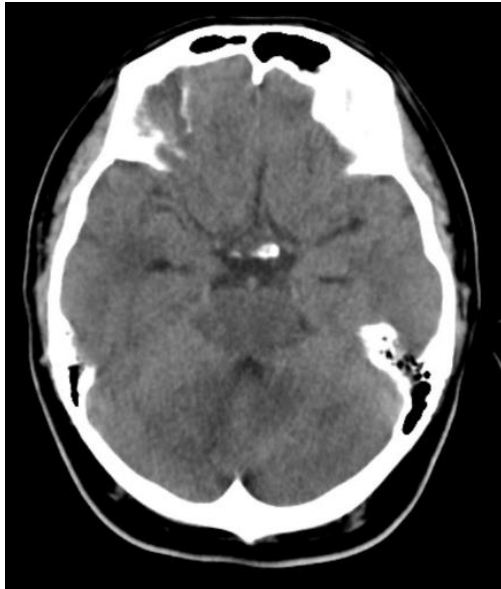

Figure 1: Hypodense area in pons, midbrain and right cerebellum with effacement of gyri and sulci

A 37-year-old male with a background history of type-2 DM for five years was brought to the emergency department (ED). His treatment included subcutaneous NovoRapid (insulin aspart) 15 units every eight hours, subcutaneous insulin detemir (Levemir®) 34 units, and metformin 500 mg daily. His DM was poorly controlled, with an HbA1c of 16.8% in September 2015. The patient was not compliant with his medication and used traditional treatment with diet control. He also had a strong family history of DM, with two diabetic siblings on insulin. He presented to the hospital with a history of

weakness, severe headache, slurred speech, and restlessness for two days. His Glasgow Coma Scale was 15/15. Clinical examination revealed a blood pressure of 172/102 mmHg, heart rate of 120 beats/min, respiratory rate 22 breaths/min, temperature 36.7°C, and capillary blood sugar 32.9 mmol/L. The remaining examination was unremarkable. Laboratory investigations revealed severe metabolic acidosis with an arterial blood pH of 7.14 and bicarbonate of 9.5 mmol/L. The patient’s arterial pCO₂ and pO₂ levels were 16.6 mmHg and 69.8 mmHg, respectively. He had two episodes of seizures and required intubation for airway protection. After intubation, he developed cardiac arrest. The possible causes were severe metabolic acidosis and brainstem infarct, as evidenced by an immediate computed tomography (CT) brain scan in the ED (Figure 1).

The patient was admitted to the intensive care unit (ICU) with a diagnosis of severe DKA and cerebellar and brainstem infarct. His HbA1c in the ICU was 9.9%. His urine was persistently positive for ketones. A complete sepsis workout, including blood culture, tracheal aspirate, and urine culture and sensitivity, was performed to identify any possible sources of infection. Further investigations of sodium, potassium, urea, glucose, and calculated osmolality are displayed in Figure 2.

The patient arrived in the ICU with double vasopressor support. An infusion of 20 µg/h fentanyl and 100 mg/h propofol was initiated for cerebral protection. Diabetic nutrition of 20 ml/h was started for feeding. Actrapid® insulin infusion was started at 6 units/h and then reduced to 3 units/h when the capillary blood sugar dropped to 10.7 mmol/L. Intravenous 0.9% normal saline at a rate of 250–500 ml/h was administered to correct the

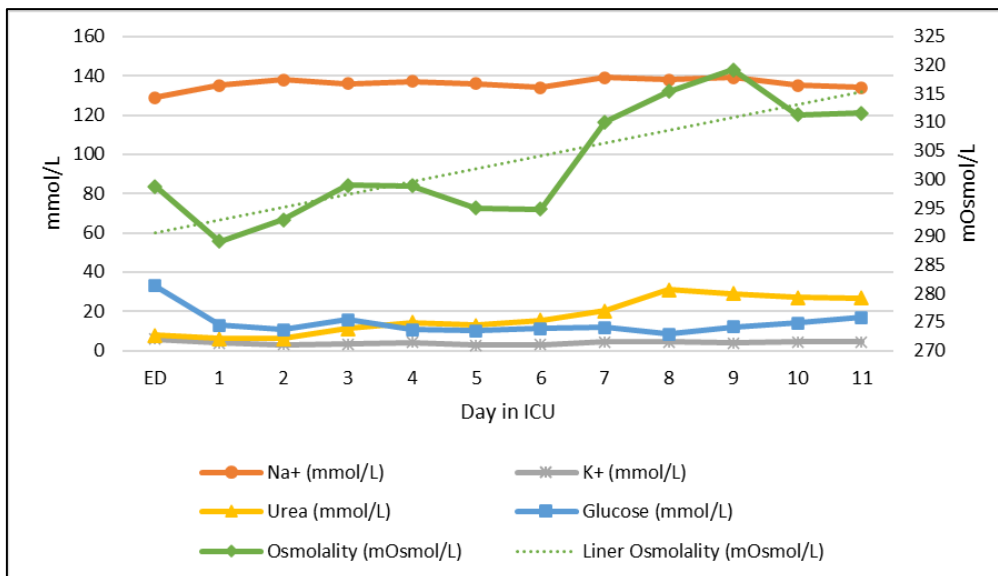


Figure 2: Laboratory results for sodium, potassium, urea, glucose, and calculated osmolality

dehydration and was guided by clinical assessment and bedside echocardiography to determine the patient’s fluid status. Potassium chloride (KCl) 1 g and sodium bicarbonate (8.4% NaHCO₃) 20 ml/h were administered to correct the hypokalemia. The total fluid initially given to the patient in the ED was 4 L, which was run rapidly from 2:45 PM until 9:00 PM. The urine output

was 3.5 L. The total fluid input and output given to the patient in the ED and ICU are shown in Figure 3. Meropenem 1 g every eight hours and vancomycin 1 g 12 hourly were given intravenously for empirical treatment of sepsis with presumed respiratory infection and possible central nervous system infection. No antiplatelet or anticoagulation therapy was administered to the patient to manage the DKA and stroke because there was derangement in the coagulation profile and thrombocytopenia as shown in Figure 4. The acidosis improved on the fourth day, and he was able to be tapered down from the inotropes. However, his blood glucose level fluctuated and could not be maintained within the target range of glycemic control (6.0–10.0 mmol/L). Insulin was adjusted to treat the hyperglycemia according to blood glucose levels, with an infusion range of 1.5–8.0 ml/h. *Klebsiella pneumoniae* bacteremia was still unresolved at day 11, and the patient continued to require noradrenaline infusion. The patient succumbed to death after 13 days.

3. Discussion

It is universally agreed that the most important initial treatment plan in DKA is adequate fluid replacement together with insulin administration. According to Malaysian Clinical Practice Guidelines, 500–1000 ml 0.9% sodium chloride (NaCl) and a fixed rate of 0.1 unit/kg/h insulin infusion are administered to the patient intravenously during the first one hour.³ For the second to sixth hour of treatment, fluid replacement needs to be continued with 1000 ml of 0.9% NaCl with KCl over two hours, followed by 1000 ml of 0.9% NaCl with KCl for two hours. The targets for metabolic treatments include reducing the blood ketone concentration by 0.5 mmol/L/h, increasing the venous bicarbonate by 3.0 mmol/L/h, reducing the capillary blood glucose by 3.0 mmol/L/h, and maintaining potassium within a range of 4.0–5.0 mmol/L. Insulin and intravenous fluid infusion rates need to be enhanced if these targets are not met.

It is necessary to administer glucose by infusion to prevent hypoglycemia in a patient with a drop-in blood glucose level below 14.0 mmol/L during insulin infusion. Early termination of insulin due to normal or low blood

glucose levels is not appropriate management in DKA. Glucose 10% is suggested when the blood glucose is lower than 14.0 mmol/L and continues with 0.9% NaCl to correct the circulatory volume. In CED, however, infusion of the glucose-containing solution might worsen the CED and secondary brain insult due to the movement of water from hypotonic to hypertonic tissue; thus, glucose-containing solutions should be avoided in patients with CED.⁴ The management of both situations is difficult. As a result, the blood glucose was not well-controlled in our patient. He required up to four days to control his DKA state.

Bicarbonate is not recommended because there is no difference in acidosis resolution, and it may increase the risk of hypokalemia and CED. However, in this case, it was administered to maintain normokalemia. The presentation of DKA-related stroke may imitate that of CED, but it requires different management strategies, so it is essential for the clinician to be aware of these potential complications. Patients with DKA need careful monitoring of their neurological condition for at least 48 h after the presentation, even if their metabolic disorders have stabilized.

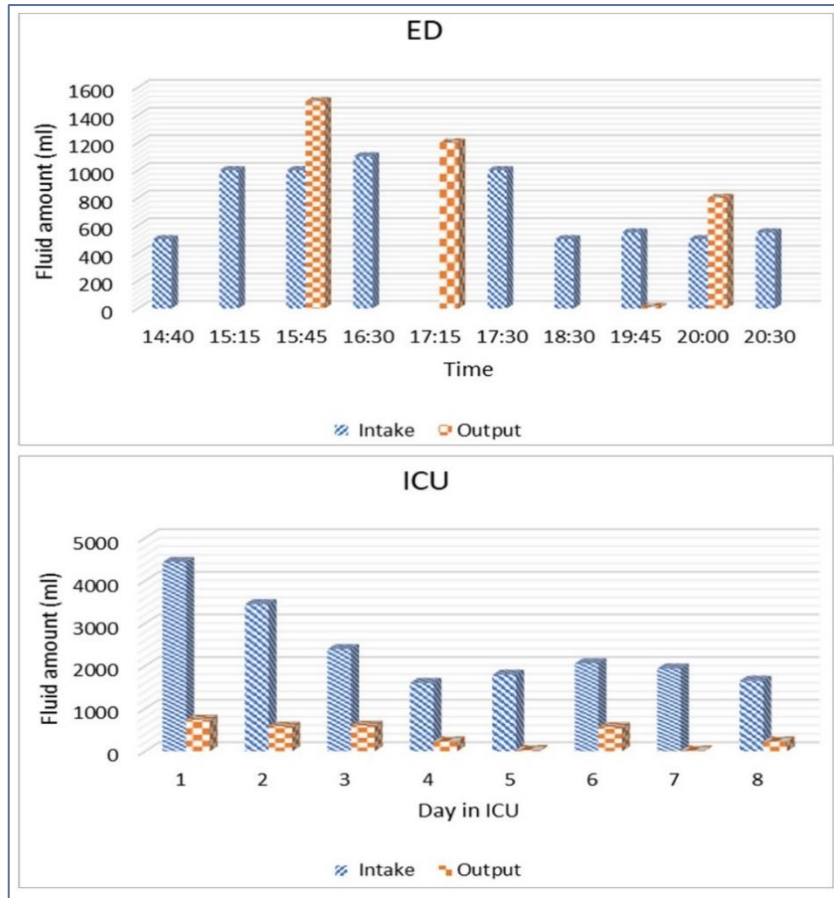


Figure 3: Total fluid input and output in the ED and ICU

Starling forces applied at the blood-brain barrier can predict increases in intracerebral extracellular fluid volume. Carlotti et al. suggested that constant insulin infusion should be administered rather than an insulin bolus because the only second-to-minute emergency caused by insulin is life-threatening hyperkalemia. The infusion of normal saline or balance solution such as Sterofundin® ISO should be given quickly when there is a crucial degree of hypotension. Carlotti et al. advised that identifying the proper target for an increase in plasma sodium is important in DKA patients because it can be associated with high morbidity and mortality.⁵ These disorders can be managed successfully by clarifying the underlying pathophysiological mechanisms.

In this case, fluid management was difficult given the ischemic brain conditions. The risk of CED and worsening ischemia is of utmost importance despite the need to rehydrate the patient. DKA may recur due to stopping or reducing the insulin dose at an inappropriate time or secondary to uncontrolled infection with inappropriate antibiotic choice and dosing.

4. Conclusions

In conclusion, DKA and stroke with CED in the ICU are difficult to manage and carry high morbidity and mortality. Careful balancing between the risk and benefit of each diagnosis and treatment is essential.

5. Acknowledgment

The authors would like to acknowledge Hospital Universiti Sains Malaysia for providing the facilities and staff in completing this study.

6. Conflict of interest

None declared by the authors.

7. Authors' contribution

NJMZ: Conduct of the study work

MZM, FMS: Concept, manuscript editing

8. References

1. Usman A, Syed Sulaiman SA, Khan AH, Adnan AS. Profiles of diabetic ketoacidosis in the multiethnic diabetic population of Malaysia. *Trop J Pharm Res.* 2015;14(1):179–85. DOI: [10.4314/tjpr.v14i1.25](https://doi.org/10.4314/tjpr.v14i1.25)
2. Edge JA, Hawkins MM, Winter DL, Dunger DB. The risk and outcome of cerebral edema developing during diabetic ketoacidosis. *Arch Dis Child.* 2001;85(1):16–22. [PubMed] DOI: [10.1136/adc.85.1.16](https://doi.org/10.1136/adc.85.1.16)
3. Clinical Practice Guidelines, Management of Type 2 Diabetes Mellitus. 5th ed. Putrajaya: Malaysian Endocrine & Metabolic Society (MEMS) Department; 2015.
4. Jha SK. Cerebral edema and its management. *Med J Armed Forces India.* 2003;59(4):326–31. [PubMed] DOI: [10.1016/S0377-1237\(03\)80147-8](https://doi.org/10.1016/S0377-1237(03)80147-8)
5. Carlotti APCP, Bohn D, Halperin ML. Importance of timing of risk factors for cerebral edema during therapy for diabetic ketoacidosis. *Arch Dis Child.* 2003;88(2):170–173. [PubMed] DOI: [10.1136/adc.88.2.170](https://doi.org/10.1136/adc.88.2.170)

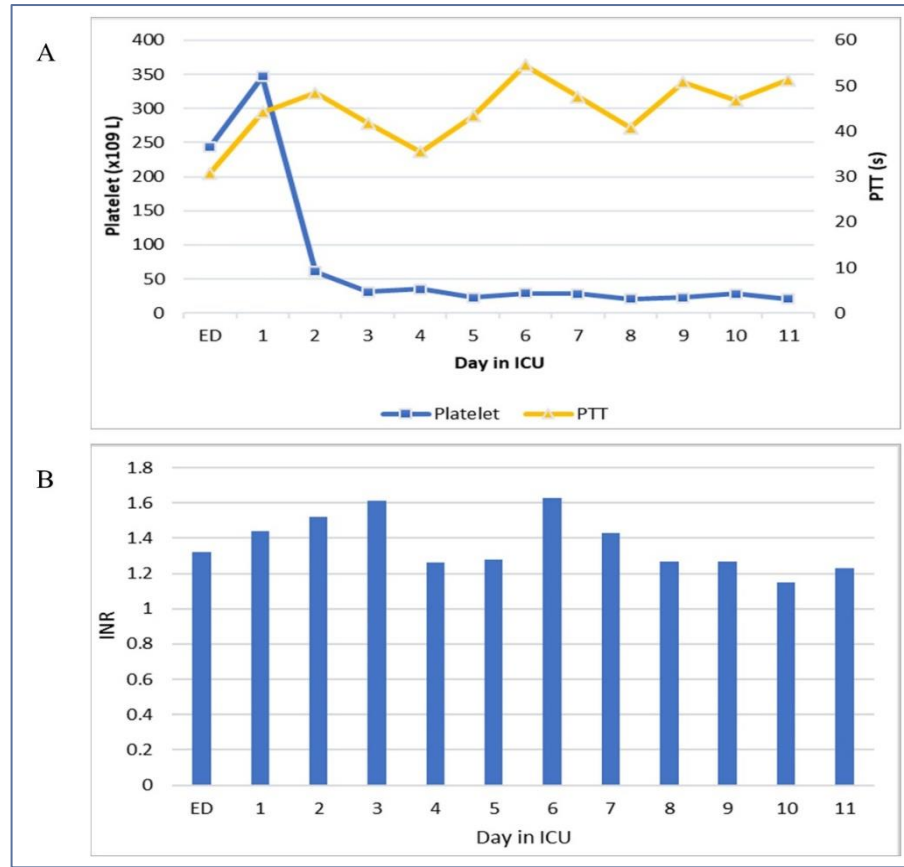


Figure 4: Profile of coagulation and thrombocytopenia (A) and international normalized ratio (B)